Sonographic Evaluation of the Distal Iliopsoas Tendon Using a New Approach

Ramon Balius, MD, PhD, Carles Pedret, MD, PhD, Marc Blasi, Maribel Miguel, MD, PhD, Beatriz Vallejo, MD, Eric Margalet, MD, PhD, David A. Bong, MD, Carlo Martinoli, MD, PhD

Sonography of the iliopsoas tendon plays an important role in the diagnosis and preoperative and postoperative management for the increasing number of patients under consideration for arthroscopically guided hip interventions such as iliopsoas tenotomy in a variety of conditions, including arthropathy, periarticular calcifications, and cam-type deformities of the femoral head. The ability to visualize the iliopsoas tendon preoperatively can be helpful diagnostically in patients presenting with hip pain and can aid in planning surgery, while evaluating the tendon postoperatively is important in the assessment of causes of postoperative pain and other potential complications. We present a novel technique for visualizing the distal iliopsoas tendon complex in the longitudinal axis at its insertion on the lesser trochanter on sonography.

Key Words—hip arthroscopy; iliopsoas tendon; musculoskeletal ultrasound; sonography

Received January 30, 2014, from the Catalan Sport Council, Generalitat de Catalunya, Barcelona, Spain (R.B.); Clínica Diagonal, Barcelona, Spain (R.B., C.P.); Centre de Diagnòstic per la Imatge de Tarragona, Tarragona, Spain (C.P.); Clínica Mapfre de Medicina del Tenis, Barcelona, Spain (C.P.); Department of Fundamental Care and Medical-Surgical Nursing, University School of Nursing, Bellvitge Health Sciences Campus, University of Barcelona, Barcelona, Spain (M.B.); Human Anatomy and Embryology Unit, Department of Experimental Pathology and Therapeutics, Faculty of Medicine, Bellvitge Campus, University of Barcelona, Barcelona, Spain (M.M.); Institut Margalet de Cirurgia Artroscòpica i Traumatologia, Barcelona, Spain (B.V., E.M.); Instituto Poal de Reumatologia, Barcelona, Spain (D.A.B.); and Department of Radiology, Dipartmento di Discipline Chirurgiche, Morfologiche e Metodologie Integrate, University of Genoa, Genoa, Italy (C.M.). Revision requested February 14, 2014. Revised manuscript accepted for publication February 20, 2014.

We thank the reviewers for their useful advice.

Address correspondence to Carles Pedret, MD, PhD, Clínica Mapfre de Medicina del Tenis, Muntaner 40, 08011 Barcelona, Spain.

E-mail: carlespedret@gmail.com

Abbreviations

FABER, flexion-abduction-external rotation; MRI, magnetic resonance imaging

doi:10.7863/ultra.33.11.2021

Unlike avulsion and apophyseal injuries of the iliopsoas tendon at the lesser trochanter, which are commonly seen in children and adolescents, spontaneous tendon ruptures in adults are rare.[1,2] However, accurate imaging of the distal iliopsoas tendon is gaining importance with the increasing use of hip arthroscopy, specifically for iliopsoas tenotomy in the transitional region between the femoral head and the femoral neck.[3–6] Therefore, the ability to visualize this structure both before and after tenotomy is of great utility. Magnetic resonance imaging (MRI) is often used to confirm and characterize the results of the procedure, but MRI is a relatively expensive diagnostic method, which does not yield dynamic images in real time and is poorly tolerated by potentially claustrophobic patients.

The distal iliopsoas is actually a musculotendinous complex formed by the main tendon from the psoas muscle and the fibers of the medial portion of the iliacus muscle with 2 components: an accessory tendon, which extends only from the iliacus muscle; and a muscle component in the most lateral part of the complex, which extends from the iliacus muscle and inserts onto the anterior side of the lesser trochanter and the subtrochanteric region (Figure 1A). Previous authors have explained that the anatomy of the iliopsoas complex is more complicated than it might initially seem and have used an MR arthrography to describe a thin intramuscular tendon separated from the iliopsoas tendon by a fatty fascial cleft.[7–10]

The aim of this report is to present a new technique, along with its advantages, for sonographic evaluation of the distal iliopsoas tendon complex using longitudinal imaging and the flexion-abduction-external rotation (FABER) maneuver to position the hip and lower extremity as opposed to routine positioning with the hip in simple abduction and external rotation. The first part of the study was performed on cadaveric specimens. After an initial sonographic examination with the hip positioned by both the FABER maneuver and the routine manner, stratographic dissection was performed to verify that the structure visualized was the iliopsoas tendon and to confirm the anatomic relationships of the tendon with the structures in this region. Transverse sections using a band saw were also obtained along the axis of the probe on frozen cadaveric specimens. The second part of the study was a reliability exercise involving healthy volunteers who were studied by 2 expert sonographers independently comparing visualization of the tendon in both positions. In the final part of the study, a of group patients who had undergone tenotomy were examined by one of the authors; 3 of the patients were examined both preoperatively and postoperatively. We found that visualization of the distal iliopsoas complex from the femoral head to its attachment site on the lesser trochanter in the longitudinal axis is improved with the FABER maneuver, provided that the hip is forcibly placed in flexion, abduction, and external rotation (Figure 1B). Anisotropy of this tendon is minimized by the almost perpendicular orientation thus achieved between the transducer and the tendon achieved by this position.

Materials and Methods

The cadaveric portion of the study was approved by the Anatomical Donations Department and performed in the Human Anatomy and Embryology Unit, Department of Experimental Pathology and Therapeutics, Faculty of Medicine, Bellvitge Campus, University of Barcelona. The studies on asymptomatic volunteers and patients who had undergone tenotomy were performed at the Medical Services Clinic of the Catalan Sport Council. Ethics approval was granted from the Human Research Ethics Committee of the Catalan Sport Council. Informed consent was obtained from all participants involved in the study.

Figure 1. Anatomy of the distal iliopsoas tendon. **A**, With the thigh in abduction and external rotation, note that the distal iliopsoas complex extends to the medial thigh. **B**, When placing the thigh in the FABER position, the lesser trochanter (arrow) is lifted, allowing visualization of the distal iliopsoas tendon in full. ILM indicates iliac muscle; and PM, psoas muscle.

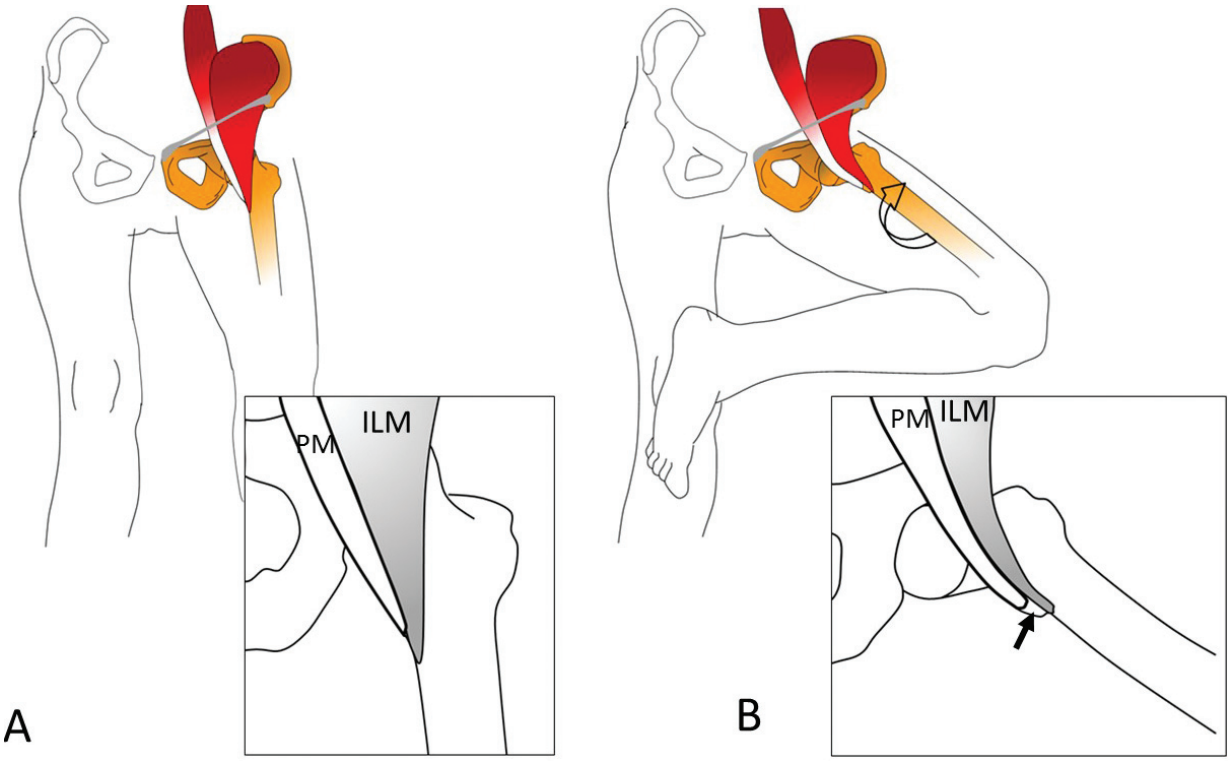

Description of the Technique

To achieve the long-axis view of the iliopsoas tendon, the lateral aspect of the foot of the limb to be studied was placed on top of the contralateral knee at the level of the suprapatellar recess, just above the upper edge of the patella (the FABER maneuver) (Figure 2A). This position involves hip flexion and abduction, and the patient is then asked to externally rotate the hip joint as far as possible. The transducer is initially placed over the femoral head in a slightly oblique (from true longitudinal) fashion, approximating the trajectory of the iliopsoas tendon as it crosses over the hip joint, and the iliopsoas tendon, which rests on top of the capsule, is then located longitudinally. In this position, it is easy to follow the tendon distally to its insertion on the lesser trochanter (Figure 2, A and B). The same sonographic evaluation was also performed with the thigh in the conventional position of abduction and external rotation (Figure 2, C and D). The positioning of the extremity and scanning technique were the same for both cadavers, healthy volunteers, and patients.

Cadaveric Study

Seven cryopreserved lower limbs from 1 male and 3 female cadavers (4 right legs and 3 left legs), with a mean age of 68 years (range, 57–89 years) were studied. The specimens were allowed to thaw at room temperature for 12 hours before sonography was performed with a LOGIQ P6 ultrasound system (GE Ultrasound Korea, Ltd, Seongnam, Korea) using a high-frequency linear transducer (6–15 MHz) with a length of 50.4 mm. The depth used was 5 cm, with a single focus at 1.8 cm and a dynamic range of 69. A sonographic examination with the specimens positioned according to the FABER maneuver was performed to identify the distal iliopsoas tendon complex. The examinations were performed by one of the authors (R.B.) with greater than 20 years of experience in musculoskeletal sonography.

Figure 2. Sonographic examination of the distal iliopsoas tendon. **A**, FABER position and insertion of the transducer. **B**, Sonogram of the distal iliopsoas tendon (arrows) using the FABER position. **C**, Normal positioning in abduction and external rotation and placement of the transducer. **D**, Sonogram of the distal iliopsoas tendon in abduction (ABD) and external rotation (ROT EXT). FH indicates femoral head; FV, femoral vessels; and LT, lesser trochanter.

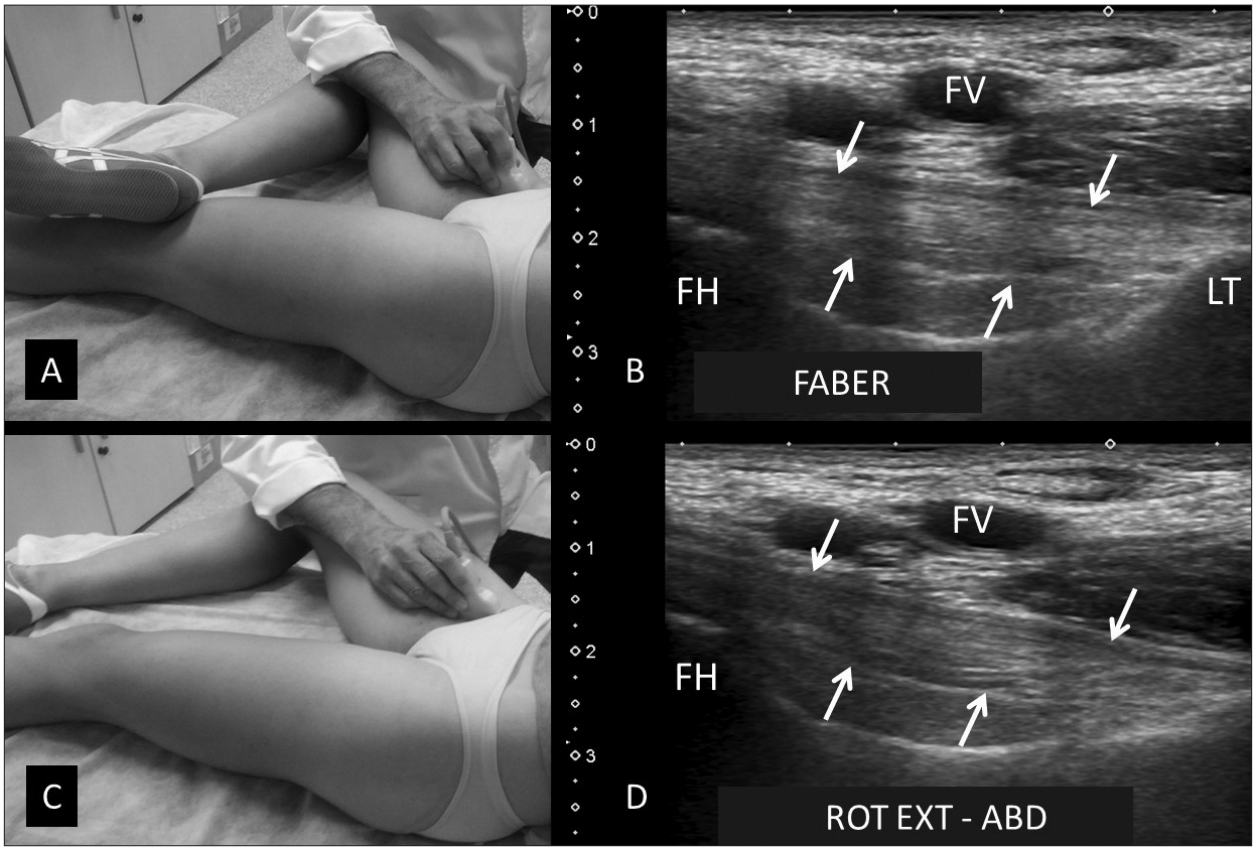

Stratographic dissection was performed on 5 of the specimens by 2 experienced anatomists (M.M. and M.B.). The position of the ultrasound transducer over the distal iliopsoas tendon complex had been marked with a surgical marker to orient the dissection. The skin and the superficial fascia of the inguinal region were first removed, followed by the cribrosa fascia. The femoral vessels were dissected, and all of their branches were removed except for the medial femoral circumflex vessels. The femoral nerve was isolated and pulled aside, together with the remaining femoral vessels, to reveal the distal course of the iliopsoas muscle to its insertion on the lesser trochanter and its relationship with the relevant surrounding anatomic structures in both the standard and FABER positions.

The transverse sections on the 2 remaining intact specimens were obtained by using a band saw after they had been refrozen for more than 72 hours at –41°C after sonographic examination of the thawed extremity. The sections were oriented along the long axis of the transducer over the iliopsoas tendon (with the specimen positioned according to the FABER maneuver), which had been drawn on the surface with a surgical marker.

Healthy Volunteer Study

Sonographic examinations of the distal iliopsoas tendon complex were performed on 20 healthy volunteers (15 male and 5 female; mean age, 25.4 years; range, 19–34 years) with no history of hip or groin conditions at the Medical Services Clinic of the Catalan Sport Council by 2 experienced sports medicine physicians (R.B. and C.P.), each with greater than 20 years of experience in musculoskeletal sonography. The sonologists performed bilateral examinations of the distal iliopsoas tendon complex on each of the volunteers independently. Both tendons were imaged in both the standard position and using the FABER maneuver, and the sonologists recorded which position best enabled visualization of the tendon or whether the visualization was equivalent in each position. Each tendon was also measured at its point of maximum thickness in each position.

Surgical Patients

Sonographic examinations of the distal iliopsoas tendon complex in both positions were also performed on 10 patients (7 male and 3 female; mean age, 32.4 years; range, 20–49 years) who had undergone a total of 13 arthroscopic iliopsoas tenotomies (3 patients had undergone a second tenotomy on the same extremity) from the Institut Margalet de Cirurgia Artroscòpica i Traumatologia by one of the authors (R.B.). Nine cases had undergone procedures for varying degrees of arthropathy due to femoral acetabular impingement, measured by using the scale of Tönnis et al,[11] and 1 had bilateral snapping hip syndrome. Three of the patients were examined both preoperatively and postoperatively. Once again, the sonologist recorded which position best enabled visualization of the tendon or whether the visualization was equivalent in each position. Each tendon was also measured at its point of its maximum thickness in each position. He also evaluated the clinical outcomes of the surgical procedures.

All sonographic studies were performed with an Aplio 400 ultrasound system (Toshiba Medical Systems, Nasu, Japan) using a high-frequency 5–12-MHz linear transducer (model PLT 805AT) with a length of 67 mm and a viewing width of 58 mm. The depth was 6 cm, with a single focus at 2 cm, and the dynamic range was 65.

Results

Cadaveric Study

The sonologist (R.B.) noted that in all the cadaveric specimens, visualization of the distal iliopsoas tendon complex was enhanced by use of the FABER maneuver as opposed to routine positioning and enabled identification of the entire distal tendon from the point where the tendon crossed the hip joint capsule to its insertion at the lesser trochanter. Stratographic dissection of 5 of the specimens and the sawed sections of the 2 remaining specimens clearly identified the structure studied by sonography as the distal iliopsoas tendon complex. The sawed sections allowed visualization of the entire distal tendon in its longitudinal axis to the insertion site on the lesser trochanter, corresponding directly to the sonograms (Figure 3).

Healthy Volunteer Study

In the sonographic reliability study, the overall agreement for the superiority or equivalence of the positioning of the leg in visualization of the distal iliopsoas complex was 85% between the examiners. Of this overall percentage of concordance, the examiners agreed that in 67.5%, the iliopsoas complex was easier to visualize with the FABER maneuver, whereas in the remaining 17.5%, the two positions were deemed equivalent in terms of image quality. There was lack of agreement in 6 hips (15%). The mean thickness of the iliopsoas measured was 6.1 mm (range, 5.5–7.6 mm): 6.2 mm (range, 4.9–7.4 mm) on the right side and 6.0 mm (range, 4.4–7.6 mm) on the left.

Surgical Patients

In the examinations of the 10 patients (13 hips) who had undergone arthroscopic iliopsoas tenotomy, postoperative

visualization using the FABER maneuver was thought to be superior, with visualization being equivalent in the remainder. The 3 cases evaluated before surgery allowed clear observation of the relationship between the psoas tendon and femoroacetabular impingement, which was characterized by an alteration of the tendinous echo structure and tautness of the tendon, which appeared to be caused by stretching at the site of conflict between the tendon, with calcifications and irregularities found on the anterior aspect of the injured joint (Figure 4). The examinations performed after tenotomy showed a clear increase in tendon thickness, which averaged 8.7 mm (range, 5.8–11.4 mm), with a slightly altered echo structure and loss of characteristic tautness (Figure 5). In 3 cases, the patient reported a regular outcome (partial or insufficient response) of the tenotomy (cases 2, 5, and 7), and in these cases, the tendon remained taut or was only minimally thickened (Table 1).

In both volunteers and surgical cases, when cam-type femoroacetabular impingement (cam lesion) was present, the FABER maneuver allowed easy visualization of the entire iliopsoas tendon up to its insertion on the lesser trochanter, whereas in the volunteers and surgical cases with increased laxity of the tendon, routine positioning was sufficient to visualize the insertion of the iliopsoas. The femoral vessels were generally visualized in the plane of the iliopsoas tendon (Figure 6), but if the volunteer had increased laxity, the medial femoral circumflex vessels were only seen as a large oblique section on sonography (probe placed along the longitudinal axis), on the proximal aspect of the iliopsoas muscle-tendon unit.

Discussion

Sonographic evaluation of the iliopsoas tendon is easily accomplished at the level of the iliopectineal eminence, where the transducer is placed in an oblique position just above the hip joint and parallel to the pubic bone. At this level, one can see the iliopsoas tendon resting on the bony cortical surface of the superior pubic ramus, surrounded by the iliac muscle medially and the lateral iliac muscle above.[8] These structures are located lateral to the femoral vessels and nerve and medial to the anterior-inferior iliac spine. This classic position is often used for dynamic sonographic analysis of a snapping psoas tendon.[8,12] Indeed, Deslandes et al[13] used this position to successfully identify a number of causes of the so-called snapping hip syndrome related to the iliopsoas tendon, including the sudden flipping of the iliopsoas tendon around the iliac

Figure 3. Anatomic and sonographic study. **A**, Longitudinal anatomic image of the distal iliopsoas tendon (arrowheads). **B**, Corresponding sonogram. **C**, Anatomic section of the anteromedial side of the thigh, where the box defines the sonographic study area. Arrows indicate lesser trochanter).

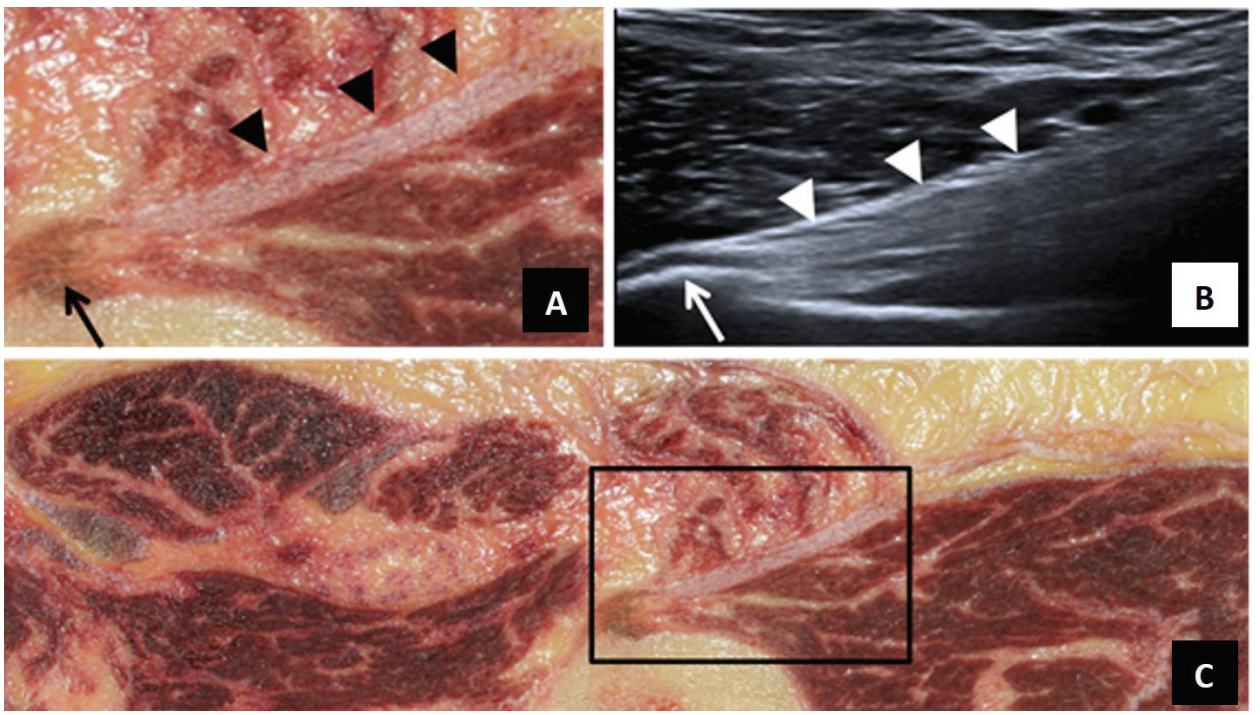

muscle, bifid tendon heads flipping over one another, and, finally, the iliopsoas tendon impinging over an anterior paralabral cyst as other causes of a snapping iliopsoas tendon. Despite the interest in this region, there are currently no references in the literature regarding a specific position that would allow clear visualization of the free part of the distal iliopsoas tendon extending from the hip joint to the lesser trochanter, the so-called distal iliopsoas complex.

The FABER test for hip region function is actually an acronym that describes the flexion-abduction-external rotation maneuver. It is also known as the Patrick test.[14,15] It provides information regarding the limitation of abduction and external rotation commonly associated with femoroacetabular impingement (FAI), as well as disorders of the sacroiliac joint. It consists of placing the foot of the leg under study on the opposite knee. It is considered normal

Figure 4. Pre- and Post-tenotomy images in a case of distal Iliopsoas tendon conflict with intra-articular bodies in the anterior facet of the coxofemoral joint in a patient with synovial osteochondromatosis. **A**, Presurgical sonogram showing a taut distal iliopsoas tendon stretched over multiple calcifications. **B**, Postoperative sonogram showing the distal iliopsoas tendon thickened and lax and the absence of intra-articular bodies. **C**, Arthroscopic image of the distal iliopsoas tendon tenotomy (arrows). **D**, Preoperative 3-dimensional computed tomographic reconstruction of the hip with extensive synovial osteochondrosis. C indicates intra-articular bodies; FH, femoral head; IPT, iliopsoas tendon; and S, synovitis.

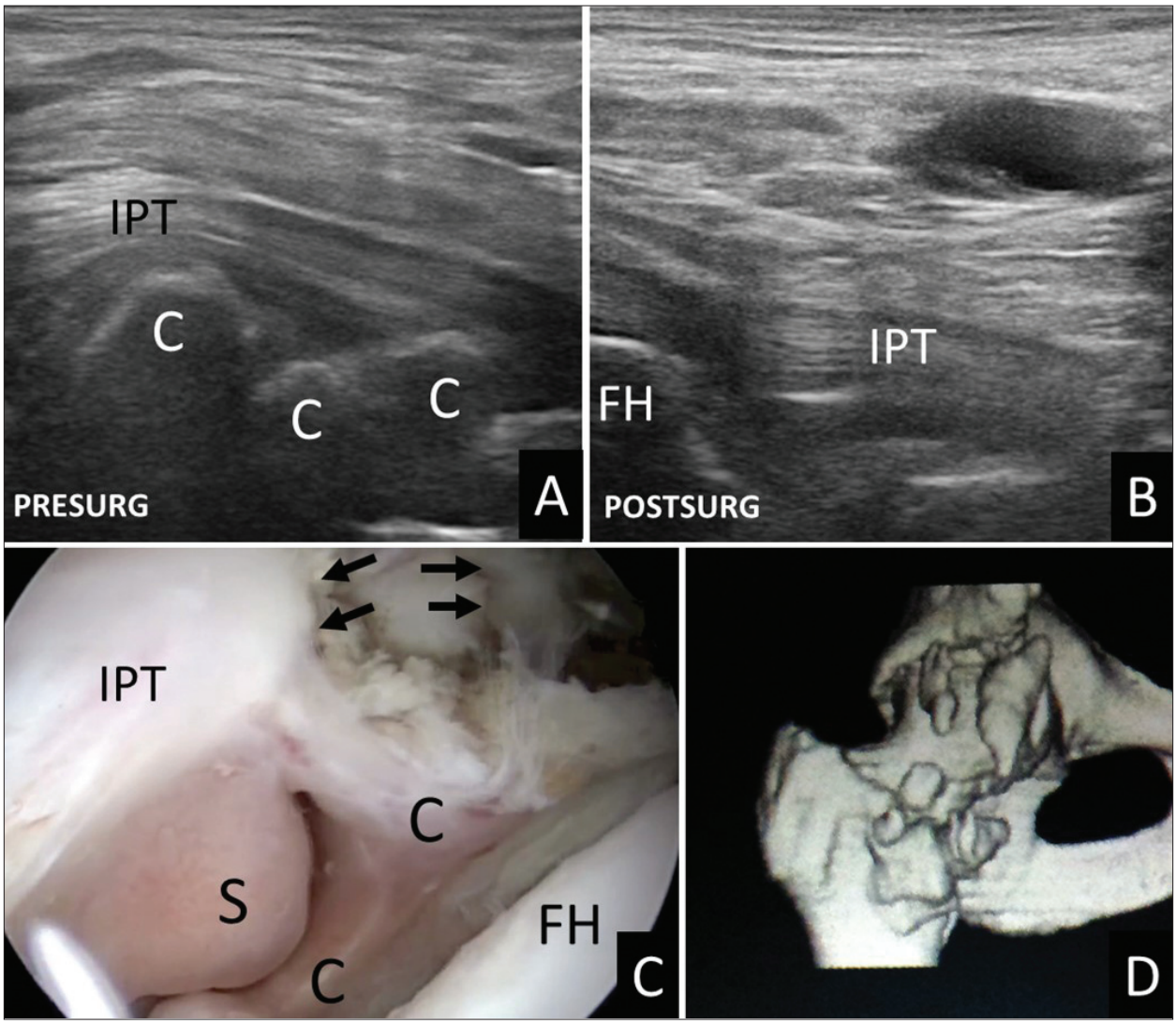

when the flexed knee is able to touch the examination table or reach a horizontal position. The test result is considered positive when the knee is clearly higher than the opposite leg.[14]

Figure 5. Three sonograms of the distal iliopsoas complex after arthroscopic tenotomy. **A**, Thickened tendon, which remains taut. **B**, Thickened and lax tendon. **C**, Lax tendon. Arrows indicate iliopsoas tendon; and FH, femoral head.

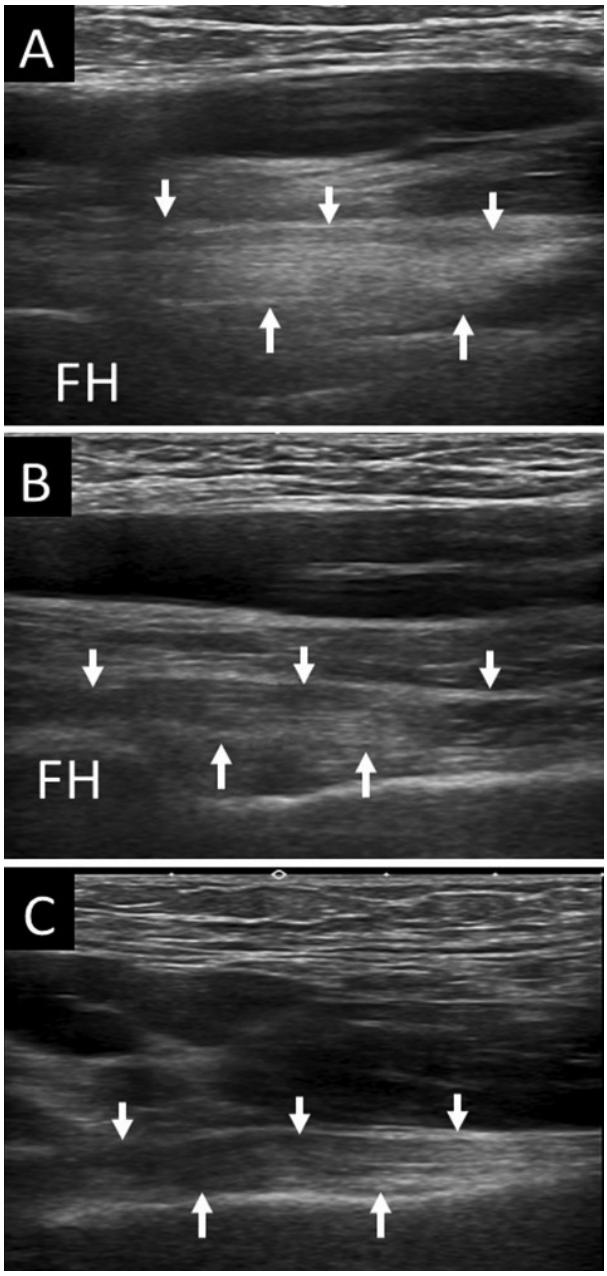

In its trajectory, the psoas tendon shows characteristic torsion, whereby the most ventral fibers twist medially and the dorsal fibers laterally. The fusion between the two tendons is gradual, with a separation of 6 to 8 cm at the posterior aspect of the tendinous complex.[7] When the hip joint is positioned in flexion, abduction, and external rotation (FABER maneuver), the lesser trochanter rotates anteriorly and thus becomes more visible on sonography. Moreover, the lower fibers of the tendon rotate medially and the upper fibers laterally. This movement corrects the natural torsion of the iliopsoas tendon and places its fibers in a state of tension with a more parallel distribution, which facilitates visualization of this structure on sonography by reducing anisotropy. This finding was evidenced in the healthy volunteers in our study. With their ability to easily place the hip in flexion, abduction, and external rotation, the tendon could be easily located up to its point of insertion on the lesser trochanter. Similarly, when rotated externally, the muscle component located in the lateral area of the distal iliopsoas complex was pulled back from the tendon component, facilitating its visualization.

Sonographically, with the limb abducted and externally rotated (Figure 7A), the iliopsoas tendon appeared as a hyperechoic and fibrillar structure extending from the hip joint almost to the lesser trochanter. The FABER maneuver allowed visualization of the entire tendon to the insertion site on the lesser trochanter (Figure 7B). Anatomically, even though the first position (Figure 7C) allowed visualization of the iliopsoas tendon, the FABER position (Figure 7D) placed the lesser trochanter more anteriorly, enabling total access to the tendon and insertion site and supporting the cadaveric sonographic findings. Also noted was that the lateral iliac muscle fibers extended distally over the lesser trochanter, attaching directly to and sharing the proximal attachment site of the vastus intermedius. Also, running relatively parallel and superficial to the iliopsoas tendon are the femoral vessels. During sonography, the medial femoral circumflex vessels (branches of the deep femoral vessels) were observed in an oblique section just superficial to the iliopsoas tendon. The oblique course of these vessels owes to the fact that they run between the iliopsoas muscle-tendon unit and the pectineus muscle and around the posteromedial aspect of the hip joint capsule.

The utility of the FABER maneuver is that it permits assessment of the actual surgical site of iliopsoas tenotomies performed during arthroscopy. Such tenotomies are performed in cases of a snapping psoas and anterior impingement of the tendon in coxofemoral arthropathy. Furthermore, the reliability study showed that this tech-

nique is reproducible between different examiners and can be included in the hip sonographic examination protocol, especially for preoperative and postoperative evaluation of arthroscopic iliopsoas tenotomy, thus avoiding the expense and inconvenience of MRI.

Sonography permits an accurate assessment of the role of the psoas tendon in cases of femoroacetabular impingement and hip arthropathy, which helps in preoperative planning, such as the need for both the removal of damaged bone and tenotomy. Post-tenotomy sonography

Table 1. Sonographic Evaluation of Surgical Tenotomies

Case	Injury	Hip Under Surgery	Result	Sonographic Aspect		Thickness, mm	
				Right IP	Left IP	Right IP	Left IP
1	Snapping psoas	Bilateral	Good	In tension	In tension	8.7	7.1
2	Tönnis grade 0	Right	Regular	In tension	Normal	8.6	5.8
3	Tönnis grade 0	Left	Good	Normal	Relaxed	6.2	8.7
4	Tönnis grade 3	Right	Good	Relaxed	Normal	11.4	10.2
5	Tönnis grade 2	Bilateral	Good (left) Regular (right)	In tension	Relaxed	7.2	7.1
6[a]	Tönnis grade 1	Right	Good	In tension	Normal	8.4	5.8
7	Tönnis grade 2	Right	Regular	In tension	Normal	5.8	5.2
8[a]	Tönnis grade 3	Bilateral	Good	Relaxed	Relaxed	9.1	9.8
9	Tönnis grade 2	Left	Good	Normal	Relaxed	6.2	10.7
10[a]	Tönnis grade 3	Left	Good	Normal	Relaxed	5.2	10.4

Good indicates excellent or satisfactory response; IP, iliopsoas tendon; regular, partial or unsatisfactory response; and Tönnis grade, arthropathy degree.
[a]Patients who had preoperative and postoperative sonographic evaluations.

Figure 6. Sonograms of the distal iliopsoas tendon complex (arrows) at its insertion on the lesser trochanter with the FABER maneuver. FLEX-ABD indicates flexion and abduction; FV, femoral vessels; and LT, lesser trochanter).

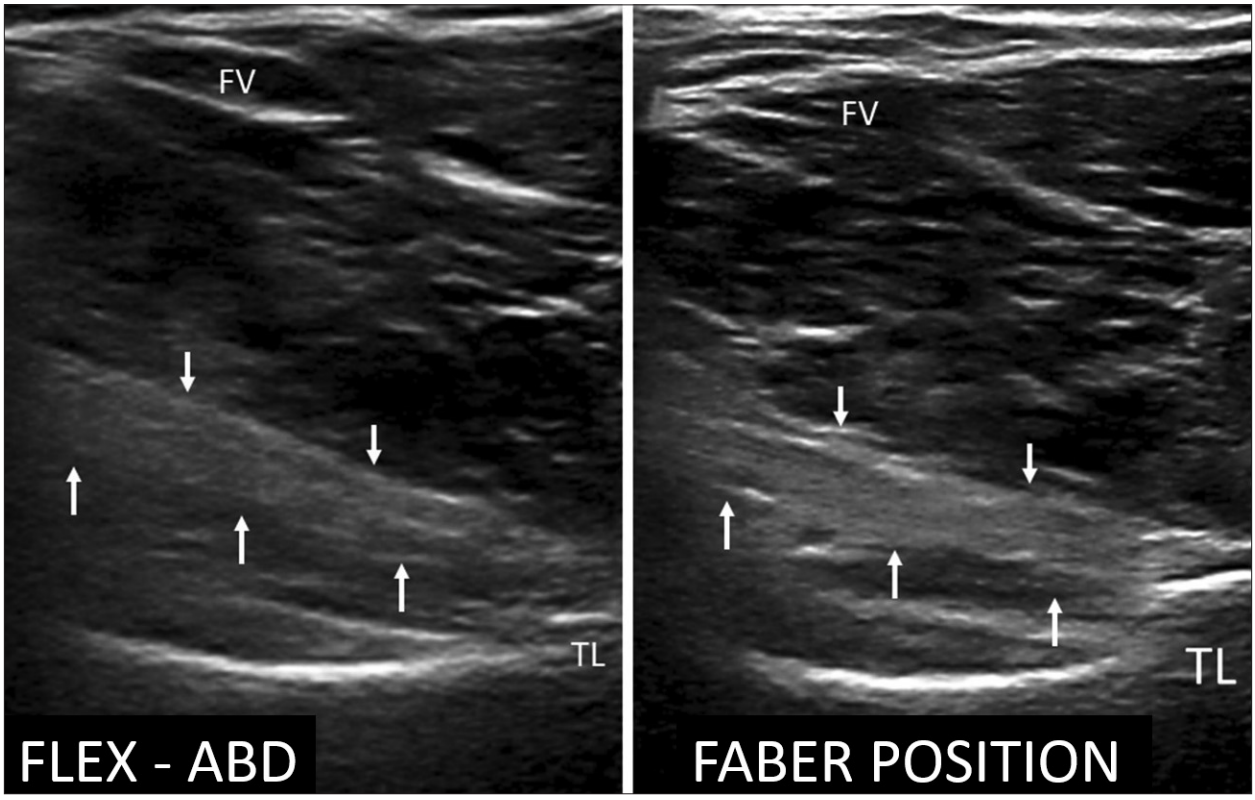

Figure 7. Anatomic-sonographic correlation. **A**, Sonogram of the distal iliopsoas tendon (arrows) visualized with the thigh only in abduction and external rotation. **B**, Corresponding anatomic image. **C**, sonogram of the distal iliopsoas tendon with the thigh in the FABER position. **D**, Corresponding anatomic image. FH indicates femoral head; FN, femoral nerve; FV, femoral vessels; LT, lesser trochanter; and MCV, medial circumflex vessels.

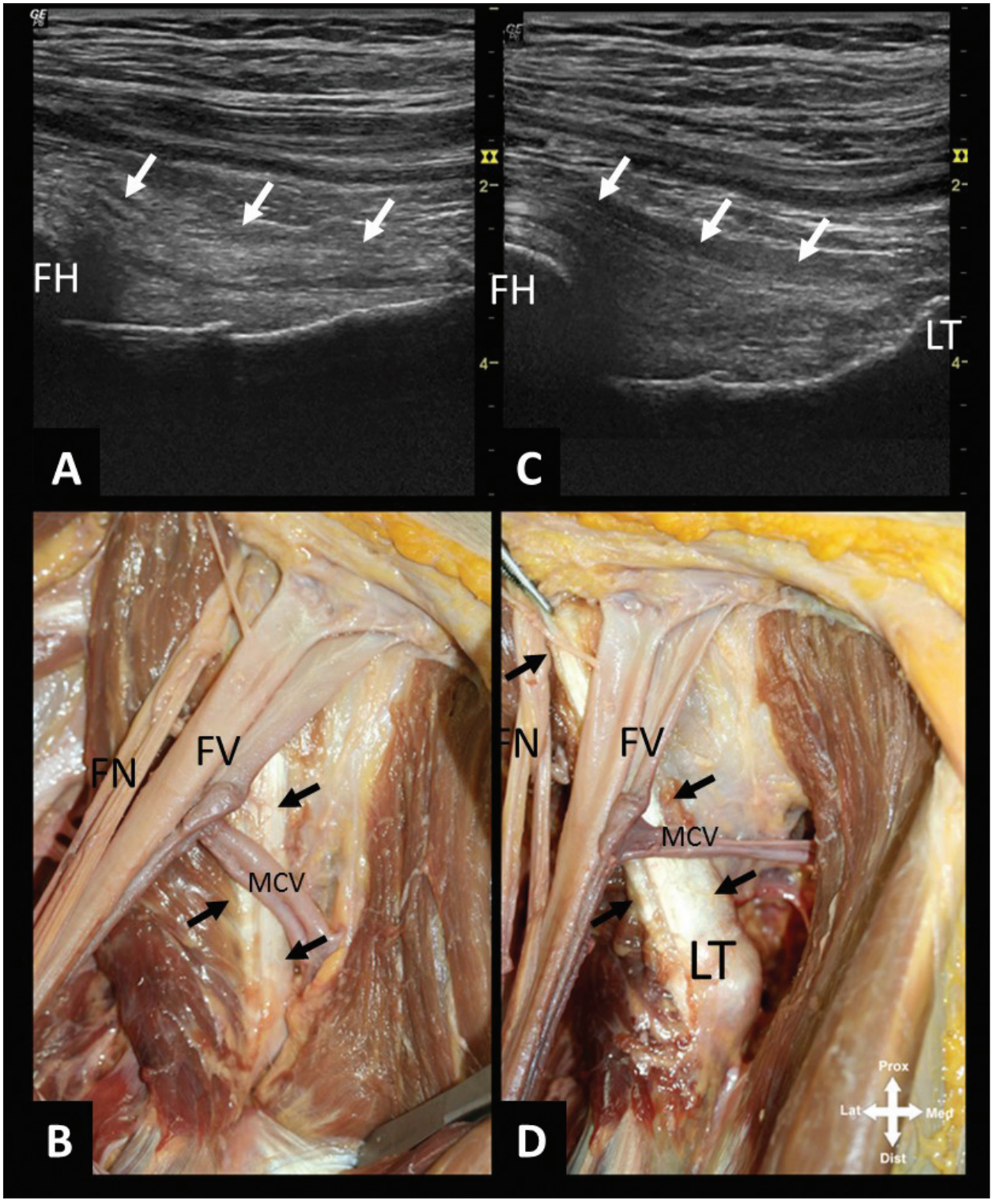

showed a characteristic pattern based on a thickening of the tendon, associated with echo structure alteration and loss of the characteristic preoperative tautness of the tendon. Of interest, in the 3 cases in which a regular outcome was observed, the tendon remained taut or minimally thickened. This appearance could possibly be an indirect sign of either a partial or insufficient response to tenotomy but obviously requires further investigation. Since it is difficult to fully visualize the tendon during arthroscopic tenotomy, sonography may help the surgeon in assessing the outcome of arthroscopic tenotomy.

In conclusion, the sonographic technique using the FABER maneuver achieved a complete longitudinal view of the distal iliopsoas tendon up to its insertion on the lesser trochanter. This technique is relatively simple, streamlines management, and can help surgeons evaluate the tendon postoperatively and potentially alter subsequent treatment, depending on the sonographic findings.

References

1. Theologis TN, Epps H, Latz K, Cole WG. Isolated fractures of the lesser trochanter in children. *Injury* 1997; 28:363–364.
2. Chung CB, Robertson JE, Cho GJ, Vaughan LM, Copp SN, Resnick D. Gluteus medius tendon tears and avulsive injuries in elderly women: imaging findings in six patients. *AJR Am J Roentgenol* 1999; 173:351–353.
3. Anderson SA, Keene JS. Results of arthroscopic iliopsoas tendon release in competitive and recreational athletes. *Am J Sports Med* 2008; 36:2363–2371.
4. Ilizaliturri VM Jr, Chaidez C, Villegas P, Briseño A, Camacho-Galindo J. Prospective randomized study of 2 different techniques for endoscopic iliopsoas tendon release in the treatment of internal snapping hip syndrome. *Arthroscopy* 2009; 25:159–163.
5. Wettstein M, Jung J, Dienst M. Arthroscopic psoas tenotomy. *Arthroscopy* 2006; 22:907.e1–907.e4.
6. Thorey T, Budde S, Ettinger M, Albrecht UV, Ezechieli M. Accessibility of extra-articular pathologies of iliopsoas tendon and bursitis of greater trochanter in hip arthroscopy. *Knee Surg Sports Traumatol Arthrosc* 2012; 20:2348–2352.
7. Tatu L, Parratte B, Vuillier F, Diop M, Monnier G. Descriptive anatomy of the femoral portion of the iliopsoas muscle: anatomical basis of anterior snapping of the hip. *Surg Radiol Anat* 2001; 23:371–374.
8. Guillin R, Cardinal E, Bureau NJ. Sonographic anatomy and dynamic study of the normal iliopsoas musculotendinous junction. *Eur Radiol* 2009; 19:995–1001.
9. Testut L, Latarjet A. Myologie. In: Testut L, Latarjet A (eds). *Traité d'Anatomie Humaine*. Paris, France: Doin; 1946:977–992.
10. Polster JM, Elgabaly M, Lee H, Klika A, Drake R, Barsoum W. MRI and gross anatomy of the iliopsoas tendon complex. *Skeletal Radiol* 2008; 37:55–58.
11. Tönnis D, Legal H, Graf R. *Congenital Dysplasia and Dislocation of the Hip in Children and Adults*. Berlin, Germany: Springer-Verlag; 1987.
12. Blankenbaker DG, De Smet AA, Keene JS. Sonography of the iliopsoas tendon and injection of the iliopsoas bursa for diagnosis and management of the painful snapping hip. *Skeletal Radiol* 2006; 35:565–571.
13. Deslandes M, Guillin R, Cardinal E, Hobden R, Bureau NJ. The snapping iliopsoas tendon: new mechanisms using dynamic sonography. *AJR Am J Roentgenol* 2008; 190:576–581.
14. Buckup K. Hip. In: Buckup K (ed). *Clinical Tests for the Musculoskeletal System*. Stuttgart, Germany: Thieme; 2004:154–155.
15. Martell JM. Pelvis, hip, and thigh. In: Reider B (ed). *The Orthopaedic Physical Examination*. Philadelphia, PA: Elsevier; 2005:161–200.