




ELSEVIER

Contents lists available at ScienceDirect

Injury

journal homepage: www.elsevier.com/locate/injury

The role of shockwaves in the enhancement of bone repair - from basic principles to clinical application

Rainer Mittermayr^{a,b,c,d,*}, Nicolas Haffner^{a,e}, Xaver Feichtinger^b, Wolfgang Schaden^{a,c,d,f}

^aLudwig Boltzmann Institute for experimental and clinical traumatology, Vienna, Austria

^bAUVA Trauma Center Meidling, Vienna, Austria

^cAUVA trauma research center, Vienna, Austria

^dAustrian Cluster for Tissue Engineering, Vienna, Austria

^eClinic Floridsdorf, Orthopedic and Traumatology Department, Vienna, Austria

^fAUVA Medical Board, Vienna, Austria

ARTICLE INFO

Article history:

Accepted 22 February 2021

Available online xxx

Keywords:

shockwave
non-union
delayed fracture healing
acute fracture
working mechanism

ABSTRACT

Extracorporeal shockwave therapy is a treatment modality, originally introduced into the clinic as lithotripsy, which has also been successfully used in the last two decades in the non-invasive treatment of delayed or non-healing fractures. Initially, the mechanism of action was attributed to microfracture-induced repair, but intensive basic research has now shown that the shockwave generates its effect in tissue via mechanotransduction. Numerous signal transduction pathways have already been demonstrated, which in their entirety trigger an endogenous regeneration process via cell proliferation, migration and differentiation. Clinically, these shockwave-conveyed biological signals support healing of acute, delayed and non-union fractures. The attainable outcome is comparable to surgery but avoiding an open approach with associated potential complications. These advantageous properties with a clearly positive cost-benefit ratio make shockwave therapy a first line treatment in delayed and non-union fractures.

© 2021 Published by Elsevier Ltd.

Introduction

Physiological, undisturbed fracture healing occurs normally within 3 months by a complex, tightly coordinated process. Factors potentially contributing to retardation of consolidation comprise local ("fracture personality", soft tissue condition) and systemic (comorbidities, medication, age or lifestyle habits) factors. Beyond this time of 3 months, osseous healing is defined as delayed and might need intervention. Both, surgical and non-surgical techniques are available but at present predominantly revision surgery is favored.

Among non-surgical options, extracorporeal shockwave treatment (ESWT) has emerged as a reliable and effective non-invasive modality for patients suffering from delayed or non-healing fractures. Following lithotriptic procedures, Haupt et al., a German urologist, observed cortical reactions at areas where the shockwaves propagated through the iliac bone [1]. Sticking to the theory of causing microfractures at this time thus inducing repair processes, Valchanou presented already in 1991 their first results on non-unions [2]. Tischer et al. first raised concerns of this hypoth-

esis after verifying bone formation histologically in bone samples which were treated with shockwaves far below the energy flux densities usually applied in urolithotripsy [3]. Schaden et al. could confirm this observation clinically as even a higher percentage of non-unions achieved bony consolidation with lower total amount of impulses / energy [4]. Since that time, an increasing effort in basic research provides pieces to the puzzle of the working mechanism of ESWT, changing the picture to a biological model, mechanotransduction being the preferential underlying mechanism [5-7].

Mechanism of shockwaves in bone tissue and fracture healing

A shockwave is characterized by a short-lasting acoustic impulse able to induce compressive-shear-, and tensile- forces within tissues. Physical, the pressure to time curve of shockwaves is characterized by a rapid rise within 10 ns, high peak pressure up to 100 MPa, a fast fall ($< 10 \mu\text{s}$) descending into a negative phase then finally returning to baseline values. As a sonic pulse, whether generated by a electrohydraulic, electromagnetic or piezoelectric technology, they show therefore high peak pressure, rapid rise in pressure and fall, a negative pressure phase ("suction wave"), short wave duration, and a broad range of frequencies. The translation of this physical energy into biological reactions is called mechanotransduction and can be direct or indirect. Biochemical signals

* Corresponding author.

E-mail address: rainer.mittermayr@auva.at (R. Mittermayr).

further lead to gene expression and protein synthesis, initiating a spatial and chronological concerted healing process [8].

Following the pathway of mechanotransduction it could be [7] demonstrated that shockwave application stimulate the expression of integrins on osteoblasts, particularly $\alpha 1\beta 5$. This transmembranous integrin is actively involved in the interaction between the extracellular matrix and the cell. In response to increased expression of integrins, the focal adhesion kinase (FAK) is significantly activated through elevated phosphorylation, which is key in the signal transduction pathways triggered by integrins. FAK activity increased also *in vivo* when rodent tibial defects were treated with ESWT [9]. *In vitro* experiments on mesenchymal stem cells supported this finding of increased shockwave induced phosphorylation of FAK, but via inhibition of miR-138, known as a direct inhibitor of the FAK gene during osteogenic differentiation of bone marrow stem cells [10]. FAK is known to play an important role in mechanotransduction and recently the mammalian target of rapamycin complex 1 (mTORC1) could be elucidated as an ESWT triggered upstream regulator in its phosphorylation. Furthermore, shockwave stimulation has also the ability to activate mTOR along with its successor protein S6K [11].

Changes in the transmembrane current due to increased K^+ and Ca^{2+} influx [12,13,13] is a further mechanism to deliver the information of a shockwave impulse from outside the cell to the cytoplasm.

All these alterations on the cell membrane and the extracellular matrix evoked by shockwaves stimulate numerous downstream intracellular signaling cascades.

The integrin induced phosphorylation of FAK by shockwaves was demonstrated to further activate ERK1/2 via MEK1/2, thus leading to an increased osteoblast adhesion, distribution, and migration, finally promoting fracture healing [7]. The activation of ERK and p38/MAPK via shockwaves has also shown to be involved in a bone defect model, enhancing the mitogenic cell activity dedicated for chondro- and osteogenesis [14]. Interestingly, ERK phosphorylation hence activation could also be shown via Ras and Rac1 protein in osteoblasts by superoxide radical, those amount was elevated after shockwave treatment [15,16]. Subsequently, the enhanced expression of hypoxia induced factor 1 α and vascular endothelial growth factor resulted in angiogenesis. The induction of angiogenesis following ESWT was one of the first mechanism which could demonstrate the biological reaction meanwhile proven for different cell and tissue types. ERK activation by shockwave mediated radical generation could also be verified in mesenchymal stem cells, which leads to increased stem cell proliferation and differentiation into osteoprogenitor cells via the osteogenic transcription factor CBFA1. Consequently, augmented osteogenesis occurred through shockwave induced ERK pathway dependent activation of CBFA1 transcription factor [17]. On a protein level, activation of the ERK signaling pathway increased RUNX-2 [10], which is a major transcriptional factor for osteogenesis. Similarly, RUNX-2 along with SOX-9 and BMP-4 was up-regulated in shockwave treated rodent knee osteoarthritis while apoptosis marker decreased [18]. The efficacy on cartilage and subchondral bone repair could be even more promoted when combining shockwave therapy with MSCs [19]. On the other hand, a decreased RANKL/OPG ratio was found in shockwave stimulated osteoblasts [20], thus indicating an inhibition of osteoclastogenesis. Both the increased RUNX-2 protein level and the reduced RANKL/OPG ratio promote bone healing. Affymetrix microarrays were even able to detect up-regulation of numerous different genes that do not affect osteoblast differentiation but also bone formation, skeletal development and cell homeostasis [21]. Gene expression analysis of various extracellular matrix proteins by in-situ hybridization in shockwave-exposed rodent femora revealed both spatial and temporal regulation of osteogenic cells. An upregulation of pro- $\alpha 1(I)$ -collagen, osteo-

calcin and osteopontin was detected in subperiosteal osteoblastic cells 4 days later, leading to the formation of periosteal bone. This increased gene regulation lasted until day 14, but in varying amounts and sometimes of different cellular origin. After 3 weeks, the shockwave-induced osteogenic stimulus resulted in increased bone mineral content and bone mineral density compared to the internal contralateral femoral controls [22]. *In vitro* studies of periosteal cells [23] have also shown that shockwave treatment has a stimulating effect on these cells, but in a delayed pattern, which is somehow contrary to the study conducted by Takahashi et al. [22] While on day 6 after shockwave exposure of human periosteum cells, the activity of alkaline phosphatase was de facto reduced compared to controls, it was not until day 18 that cell proliferation and elevated ALP levels were detected. As a result, increased mineralization of the extracellular matrix (ECM) was observed on day 35 [23,24]. However, not only the mineralization of the ECM is stimulated by ESWT, but also increasingly sulfated glycosaminoglycans as main matrix components were observed during 28 days after shockwave exposure [25]. Not surprisingly, also components of the intracellular matrix (in particular actin stress fibers) are influenced in response to shockwaves and mTORC1 was alternatively localized subcellularly as vesicle-like inclusion on microfilaments [11].

Tissue stimulation by shockwaves has further revealed to produce and release various growth factors directly involved in bone repair including but not limited to BMPs [26-28], TGF- $\beta 1$, and IL-10 [29] although the specific pathway was not further elucidated.

The working mechanism of ESWT could not only be shown for bone tissue and in fracture repair, but also in different other cell types and tissues. In this regard, shockwave activated intracellular signaling cascades including p38, MAPK, ERK1/2 [6,30,31], and AKT [32-35]. Additionally, it could be demonstrated that ESWT influences or induces the recruitment of stem cells partially via SDF-1 [36-40]. Schuh et al. [41] observed a prolonged expression and an overall increase in mesenchymal stem cell markers after ESWT. Earlier, Wang et al. showed that immortalized human bone marrow stromal cells respond to electrohydraulic shockwave stimulation with higher cell proliferation and osteogenic differentiation [16]. Consistently first applications of combined therapies including ESWT and autologous stem cell transplantation in patients suffering from non-unions, yielded an increase in their healing rate [42,43]. Contrary to these reports, an *in vitro* study investigating a single shockwave application on equine bone marrow derived mesenchymal stem cells could only show a modest transient osteogenic effect with an increased alkaline phosphatase protein expression at day 3 without affecting gene expression of osteogenic markers in the observed time intervals [44].

In tissue engineering approaches aiming at regeneration, biomaterials represent one of the three major components, cells and regulatory signals (i.e. growth factors, physical signals) being the other two. To enhance cell proliferation and differentiation, bone marrow derived stem cells (bMSC) were exposed to piezoelectric focused shockwaves and then transferred into a conjugate of covalently cross-linked gelatin and hydroxyphenyl propionic acid (Gtn-HPA). It could be shown that the higher energy shockwave application yielded in a significantly higher proliferation rate compared to the low energy SW and even PDGF-BB growth factor counterparts. Moreover, the osteogenic differentiation was also highest while migration was inferior to the growth factor group [45]. Interestingly, only adding the supernatant medium of high-energy SW treated bMSC to native bMSCs also resulted in higher proliferation rates within 6 days compared to controls.

Furthermore, successful orthotopic bone formation could be achieved in another study by seeding a bone scaffold with shockwave stimulated periosteal cells [46].

Table 1

Clinical studies evaluating the efficacy of extracorporeal shockwave therapy in acute, delayed and non-union fractures.

Study Authors	Publication Date	Anatomical Region	ESWT Protocol	Outcome/Conclusion
<i>Shockwave in the treatment of acute fractures</i>				
Wang et al.	2007	long bones of lower extremity	Surgery + ESWT (6000 impulses at 0.62 mJ/mm ²)	6 months/12 months: significant improvement in ESWT group
Moretti et al.	2009	tibia	Surgery + ESWT (4000 impulses at 0.07 and 0.17 mJ/mm ²)	45 days - 3 months: improvement in ESWT group
<i>Shockwave in the treatment of delayed or non-healing fractures</i>				
Beutler et al.	2000	long bones	2xESWT (2000 impulses; 18 kV)	3 months: success rate 41%
Cacchio et al.	2009	long bones	surgery vs. 4xESWT (4000 impulses; group 1: 0.40 mJ/mm ² ; group 2: 0.70 mJ/mm ²)	3/6/12/24 months: improvement in ESWT groups clinically; radiology similar to surgery
Rompe et al.	2001	tibia and femur	1xESWT (3000 impulses; 0.60 mJ/mm ²)	4 months: success rate 72%
Kuo et al.	2015	femur	1xESWT (6000 impulses; 0.58 mJ/mm ²)	9.2 months: success rate 63.6%
Elster et al.	2010	tibia	1xESWT (4000 (-12000) impulses; 0.38-0.4 mJ/mm ²)	4.8 months: success rate 80.2%
Haffner et al.	2016	tibia	1xESWT (3000-4000 impulses; 0.40 mJ/mm ²)	6 months: success rate 88.5%; significance in early vs. delayed treatment
Nada et al.	2017	tibia	3xESWT (2500-3000 impulses; 0.25-0.84 mJ/mm ²)	6 months: success rate 93.33% ESWT; success rate 73.3% PEMF
Furia et al.	2010	5th metatarsal	1xESWT (2000-4000 impulses; 0.35 mJ/mm ² , 4 Hz)	6 months: no significant radiographic differences; significantly less complications in ESWT group (1/11)
Everding et al.	2020	arthrodesis of the lower and upper extremity	1xESWT (3000 impulses; 0.36 mJ/mm ² , 4 Hz)	Osseous consolidation in 80% hand arthrodesis, 50% upper ankle arthrodesis, 27% subtalar joint
Notarnicola et al.	2010	scaphoid	surgery vs. 3xESWT (4000 impulses; 0.09 mJ/mm ²)	12 months: similar clinical and radiographic results between surgery and ESWT
Quadlbauer et al.	2018	scaphoid	surgery +/- 1xESWT (3000 impulses; 0.41 mJ/mm ² , 4 Hz)	Significantly lower VAS and better Mayo score compared with surgery alone
Fallnhauser et al.	2019	scaphoid	1xESWT (4000 impulses; 0.41 mJ/mm ² , 4 Hz)	10-12 weeks: success rate 71%
Schaden et al.	2001	different	1xESWT (1000-12000 impulses; 0.25-0.4 mJ/mm ² , 4 Hz)	3 months - 4 years: success rate 75.7%
Stojadinovic et al.	2011	different	1xESWT (4000 (-12000) impulses; 0.38-0.4 mJ/mm ²)	6 months: time to treatment and anatomic site are predictors for success
Vulpiani et al.	2012	different	3-5xESWT (2500-3000 impulses; 0.25-0.84 mJ/mm ²)	7.6 months: success rate 55.9%; trophic > atrophic
Alkhashki et al.	2015	different	1-3xESWT (2000-4000 impulses; 26 kV)	10 months: success rate 75.5%
Everding et al.	2017	different	1xESWT (3000 impulses; 0.36 mJ/mm ²)	6 months: success rate 73%; lower costs; less pain (6w)

In summary, ESWT interacts on multiple cellular and molecular levels, inducing regeneration rather than repair.

Shockwaves in the treatment of acute fractures

The successful treatment of acute fractures includes both conservative and surgical measures. Regardless of the initial treatment, careful follow-up monitoring is important and often decisive for the outcome. However, local and systemic factors can interfere with bone healing in such a way that the fracture is delayed or, in the worst case, does not heal at all. Among the factors potentially at risk of disrupting physiological healing, which can also be easily detected at initial examination, are the severity of comminuted fracture, the fracture-related extent of soft tissue injury and comorbidities such as diabetes and vascular disease. The surgical procedure (both in terms of technique and type of osteosynthesis) is of utmost importance in these precarious cases in order to avoid healing failure.

In this context, ESWT is a valuable prophylactic or complementary procedure in the surgical treatment of acute fractures, as it can be used in the same session without significantly extending the operating time. In 2007, Wang et al. were the first to investigate the effect of ESWT in acute high-energy fractures (Table 1). In this prospective randomized study, the investigators included 59 acute long bone fractures of the lower extremity [47]. Electrohydraulic ESWT was applied at the end of surgery by delivering in total 6000 impulses at an energy flux density of 0.62mJ/mm². At a follow-up of 6-month radiographic examinations revealed a significantly higher union rate in the study group compared to the control group receiving only surgery (63% versus 23%, respectively).

This difference in fracture union rate was still evident at a significant level 12 months after intervention (89 vs. 80%). Moretti et al. showed similarly accelerated healing in their case series of 16 acute closed tibial fractures, which was evident in a higher number of healed cortices. Independent radiographic analysis showed cortical continuity with an average of 3.25 in the study group versus 2.54 in the control group [48].

To support the hypothesis that shockwaves promote bone healing in acute fractures, Kieves and colleagues investigated the influence of shockwaves in a canine tibial osteotomy model [49]. In both study groups, a leveling tibial plateau osteotomy was performed and subsequently stabilized with an osteosynthesis plate. Assuming that the osteotomy is an acute iatrogenic fracture, their study showed a significantly better outcome in terms of fracture healing in the treatment group after 8 weeks. However, in contrast to Wang et al., shockwave treatment was performed at two points in time (intraoperatively after plate fixation and 2 weeks thereafter) with 1000 pulses/session initiated by an electrohydraulic device at an energy flux density of 0.15mJ/mm². Bilateral tibial osteotomies followed by internal stabilization also served as an acute model in an experimental study, but in ovariectomized rats. This has the effect of a diabetic status and thus the development of osteoporosis, which is considered a risk factor for impaired bone healing. Subsequently, the left tibia in these osteoporotic rats were shockwave treated and compared to the internal, non-treated contralateral side. MicroCT analysis showed significantly improved bone quality parameter thus indicating a beneficial effect of ESWT in experimental osteoporotic tibial fracture healing [50]. Van der Jagt et al. investigated the influence of ESWT in osteoporotic ovariectomized rodents, looking at dynamic changes of bone mi-

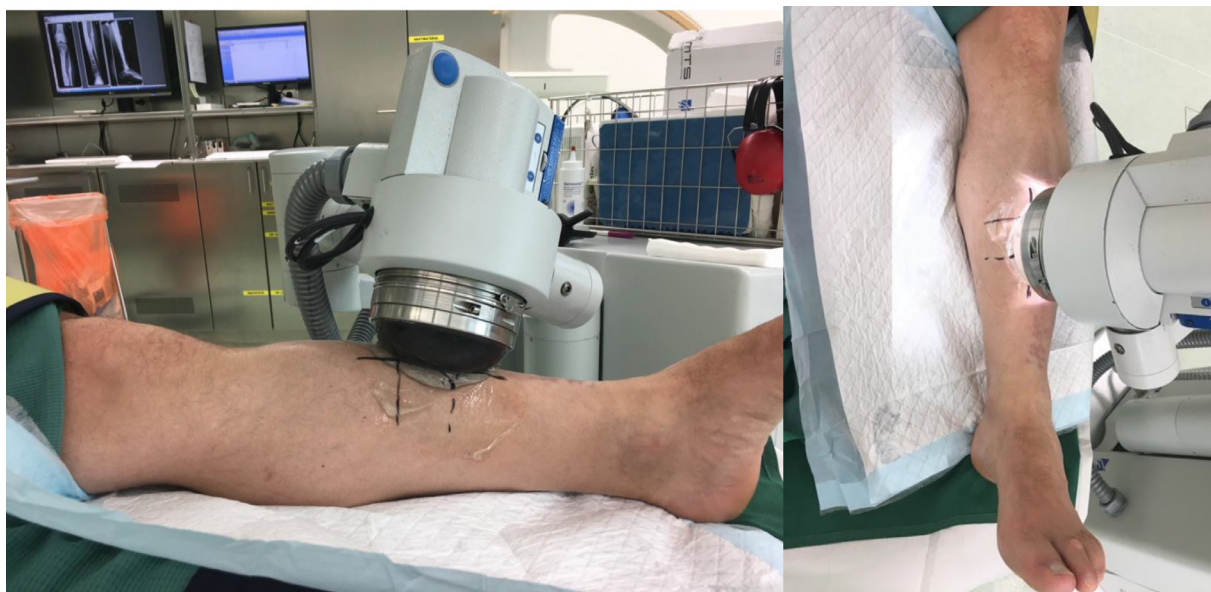

Fig. 1. Typical shockwave application of a tibial non-union under general anesthesia in the trauma center Vienna, Meidling. The non-union is located by x-ray fluoroscopy and marked on the skin. Bubble-free conduction gel is applied and the focus of the therapy head is adjusted to the fracture gap. Thereafter, electrohydraulic impulses are applied from different directions.

coarchitecture following a fibula osteotomy. A single application of 2000 pulses with an energy flux density of 0.16 mJ/mm^2 resulted in significantly higher trabecular bone volume fractions of the proximal tibia compared to the untreated contralateral side, which also persisted for up to 7 weeks after treatment. However, healing of the fibula osteotomy was not affected [51]. Single photon emission computed tomography (SPECT) analysis of healthy tibia revealed increased uptake of technetium-labeled methylene diphosphonate in response to a single shock wave application, suggesting increased metabolic activity of osteoblasts. In addition, structural analysis performed by micro-CT imaging revealed both increased trabecular and cortical volume [52], resulting in improved biomechanical properties in osteoporotic bone [53].

Prophylactic treatment with shockwaves of patients with osteoporosis prone to fragility fractures is difficult to perform or fund. However, treating osteoporosis-related fractures with ESWT at the time of surgery could improve and accelerate healing. The same applies to acute fractures in which there is a risk of postoperative bone healing disorders (e.g. open fractures, nicotine abuse, diabetes mellitus). Although the above-mentioned studies indicate a positive effect of ESWT, further randomized clinical trials are required to confirm the additive value of ESWT in acute (surgical) fracture treatment.

Shockwaves in the treatment of delayed or non-healing fractures

Over the last two decades, numerous clinical studies have demonstrated the effectiveness of ESWT in the indication of delayed or non-healing fractures [54-57]. Based on our own experience and with a case series of 115 consecutive patients published in 1998, of which 87 non-unions (corresponds to 75.7% union rate) showed bone healing 6 months after shock wave application [4], ESWT has been established in our facility as the treatment of choice for non-unions. Since then, more than 5,000 cases of delayed or non-healing fractures at various anatomical locations have been treated in our institution with focused electrohydraulic high-energy shockwaves (Fig. 1) with an average healing rate of almost 80% after six months follow-up (data not published). The reason for establishing ESWT as the standard therapy for non-healing fractures in our institution was not only the high success rate alone,

but also the almost complete absence of complications, especially compared to the so-called gold standard, revision surgery. In addition to the clear advantages of ESWT (e.g. non-invasive, high healing rate) and the fact that most patients who have already undergone multiple operations prefer not to undergo (further) major surgery with the associated risks and complications, economic considerations have also led to ESWT becoming increasingly recognized worldwide.

Following the requirements of evidence-based medicine that a treatment modality must be at least as effective, if not better, than the standard treatment, Cacchio and colleagues [56] conducted a prospective, randomized, controlled multicenter study (evidence level I). In this study, they examined the treatment effects of ESWT in unhealed long bones (radius, ulna, femur, and tibia) and compared them to the current "standard of care" surgery. To minimize bias, the study groups were carefully selected and homogeneously distributed. The shock wave treatment was performed in two different modalities, with the energy flux density set at 0.4 mJ/mm^2 (group 1) and 0.7 mJ/mm^2 (group 2). However, both groups received the same number of electromagnetic pulses generated per session at 4000 each with the focus on the fracture gap. The treatment was performed a total of 4 times at weekly intervals in both groups. The surgical control group followed a standard protocol to ensure maximum reproducibility. This protocol initially included implant removal, decortication and scar debridement in the fracture gap, reopening of the medullary canal, followed by fracture reduction and fixation, and, if necessary, autologous bone grafting. Radiologic assessment, which was the primary outcome parameter, was performed at several different points in time up to 24 months after surgery. Radiologic results showed no significant difference between study groups, and bone healing was evident in 94% of group 1 (0.4 mJ/mm^2), 92% of group 2 (0.7 mJ/mm^2), and 95% of the surgical group after 2 years. However, the visual analogue scale (VAS), the lower limb function scale (LEFS), and the arm, shoulder, and hand disabilities questionnaire (DASH) showed a significantly better outcome in the ESWT groups at both 3 and 6 months compared to surgery. In addition, no adverse events were observed in the ESWT groups, with the exception of small petechial hemorrhages and minor hematomas in 23 patients, which

subsided spontaneously without further therapy. In complete contrast, complications occurred in 7% of the patients in the surgical group. The complications were 2 revisable infections and a radial nerve paresis. This level 1 study clearly demonstrated the equivalence of bony consolidation of non-unions in long tubular bones between ESWT and surgery. In addition, ESWT appears to be superior to revision surgery in the short-term clinical and functional outcome, while avoiding serious complications completely. Treating tibial non-union, Nada et al. conducted a study in which they randomly assigned 60 patients in total equally distributed to 1) pulsed electromagnetic field treatment and 2) shockwaves [58]. They could observe union rates in the shockwave group of 93% whereas only 73% of the tibial non-unions dedicated to the pulsed electromagnetic field therapy ended up in osseous consolidation.

Another study comparing shock wave therapy with surgical revision of non-unions was conducted by Furia et al. [59]. Treatment at the base of the 5th metatarsal showed no differences in bony consolidation between groups, thus matching the effectiveness of ESWT in the previous study by Cacchio et al. [56]. The treatment protocol for ESWT consisted of a single application of 2000 to 4000 pulses at an energy flux density of 0.35 mJ/mm² (electrohydraulic, n=23). The revision of the non-union in the surgical comparison group (n=20) was performed by closed reduction and intramedullary screw fixation. No statistically significant differences in bony union between the two groups were found at 6-month follow-up radiographic examinations (91% union rate in the ESWT group vs. 90% in the surgical group). However, ESWT showed no complications except for a case of minor petechiae, while surgery resulted in a total of 11 complications. These ranged from a refracture and infection to nine cases of irritation from the osteosynthesis material, all of which required additional surgery. Based on this study, we concluded that both ESWT and screw fixation are appropriate modalities for the treatment of non-union of the fifth metatarsal base. However, the avoidance of complications is a key advantage of ESWT and could prove to be financially superior to surgery.

The scaphoid is particularly at risk of developing a non-union after a fracture due to the special anatomical conditions, especially the blood supply. Notarnicola et al. [39] included in their retrospective study primarily conservatively treated scaphoid fractures that showed no radiological consolidation after 6 months. These scaphoid non-union fractures were either treated with ESWT (n=58) or surgically revised (n=60). The parameters in the shockwave group were selected using 4000 pulses from an electromagnetic source at an average energy flux density of 0.09mJ/mm². On the basis of past experience about the necessity of several applications when using electromagnetic devices, three treatments were carried out at intervals of 72 hours. As a surgical procedure, the Matti-Russe approach was performed with a corticocancellous bone graft. In both groups, the forearm was immobilized post-interventional with a plaster fixation. For the primary target parameter of bone consolidation at 12 months, the authors again found comparable results in both intervention groups (bone healing in 79% ESWT and 78% surgery group). The Mayo score of the wrist as a clinical parameter, showed excellent and good results in 57% and 60%, respectively (ESWT vs. surgery). In contrast to our study at the base of the 5th metatarsal, no complications occurred, neither in the ESWT nor in the surgery group. Quadlbauer et al. [60] surgically revised scaphoidal non-unions older than 6 months by debridement, autologous cancellous bone grafts and fracture stabilization either with one or two headless compression screws or a palmar plate. Within 2 weeks after revision surgery, 3000 electrohydraulic focused shockwaves were applied in the ESWT group at an energy flux density of 0.41 mJ/mm² with 4 Hertz. Immobilization was scheduled for 8 weeks in both the comparison group which received only revision surgery (n=16) and the

ESWT group (n=26). A statistical non-relevant higher union rate was found in the ESWT group (81%) compared to the group which received only surgical revision (75%). However, significantly less pain and a significantly better Mayo Score could be observed in the follow-up period for the ESWT group showing additional positive effects even in surgical revisions. If shockwaves were applied only in scaphoidal non-unions without concomitant surgical intervention a union rate of almost 76% could be achieved in our retrospective analysis (results not published yet). Similarly, Fallnhauser et al. were able to observe a union rate of 71% in their patient cohort of 42 scaphoidal non-union [61]. Remarkably, none of the investigated potential influencing factors showed a significant effect on the outcome.

An interesting study was conducted by Everding et al. in a small cohort (n=24) suffering from failed osseous arthrodesis bridging of the upper and lower extremity [62]. Shockwaves were able to help these patients by bony healing in 80% (arthrodesis of the hand), 50% (arthrodesis of the ankle) and only in 25% in arthrodesis of the subtalar joint.

Unfortunately, due to the low incidence of non-unions (tibia still shows the highest figures at around 10%) and for ethical reasons, no randomized clinical trials have yet been performed comparing shockwave treatment with an untreated control group. However, the above-mentioned clinical studies showed similarly good results of ESWT in non-union fractures compared to the standard treatment, which has been performed as revision surgery.

In the absence of a control group for reasons mentioned above, additional studies have been conducted to investigate the effects of ESWT on non-union fractures. A literature review by Zelle et al. identified 10 clinical studies (primarily case series with level 4 evidence) with a total of 924 patients who had delayed or failed to heal their fracture [63]. Their overall analysis of the included studies showed an overall healing rate of 76% (95% confidence interval: 73-79%). Interestingly, the difference in bony consolidation between atrophic and hypertrophic non-unions was significant, ranging from 29% for atrophic (9 of 31) to 76% for hypertrophic (185 of 243) non-unions.

Since this 2010 review, a number of other studies have been conducted to assess the effect of ESWT in non-healing fractures. Alkhashki et al. examined a total of 49 non-unions of different anatomical locations [64], of which 38 were treated once, 9 twice and 2 three times with 2000-4000 pulses per region at 26 kV. Treatment with shockwaves resulted in a 75.5% consolidation rate in this cohort after a mean follow-up period of 10 months. An in-depth analysis revealed mechanical instability, a fracture gap of more than 5 mm, the type of bone treated (scaphoid), and a previously undetected low-grade infection as risk factors for treatment failure. In contrast, our group demonstrated that tibial non-unions showed an equivalent response to ESWT (88.5% cure rate) compared to non-infected cases [65]. Similarly, our study in a subgroup analysis of hypertrophic vs. oligo/atrophic non-unions showed no statistical difference (94% vs. 88%) in healing, which in somehow contradicts the results of a study by Vulpiani [66] and the review conducted by Zelle [63]. Nevertheless, a number of other studies confirm our findings that the appearance of non-unions (atrophic/oligotrophic, hypertrophic) is of secondary importance when considering shockwave therapy [67-69]. Our data [65] suggest that ESWT should be performed early after the last surgery or trauma to increase the likelihood of recovery. This conclusion was shared by the studies of Stojadinovic et al. [67] and Elster et al. [68].

Systemic risk factors for bony consolidation were considered by Everding et al. [69]. Interestingly, although they were found to be negative predictors in other studies, they could not demonstrate tobacco use in any negative association with ESWT treatment success. Stojadinovic et al. examined other variables to establish a

prognostic naïve Bayesian classifier that affects healing outcome after ESWT. They were able to denote previous intramedullary stabilization, number of previous bone grafts, shockwave treatments already performed, and anatomical location as relevant predictive factors [67].

Based on our own experience with more than 5,000 treatments performed on delayed or non-healing bone fractures, a clear correlation between the anatomical region/the affected bone and healing after ESWT could be seen. While tibial non-unions showed the highest response rate [65], the humerus and scaphoid showed relatively poorer results with healing rates of approximately 65% (unpublished data). Kuo et al. showed in their retrospective study a 64% consolidation in atrophic diaphyseal femoral non-unions with shockwaves [70].

Based on the numerous studies investigating the effects of ESWT on delayed or non-healing fractures (summarized in table 1), as well as data from our own database, which is probably the most comprehensive in the world with 5,000 cases, we conclude that ESWT is a valuable, efficient and cost-effective intervention and propose it as a first-line therapy for delayed healing or non-healing.

Concluding comments

Shockwave treatment, especially for delayed or non-healing fractures, is proving to be a reliable, safe and highly effective treatment overall. However, further prospective and randomized studies are needed to support these findings and to obtain further optimization of therapeutic parameters and subsequent treatment. As severe complications are completely avoided, as they do occur during surgical procedures, ESWT is the treatment of choice in these cases, at least in Austria. Its additional benefit in both acute and fragility fractures still needs to be substantiated by further studies. However, the data already available indicate a further valuable indication for shockwave therapy.

References

- Haupt G, Haupt A, Ekernkamp A, Gerety B, Chvapil M. Influence of shock waves on fracture healing. *Urology* 1992. doi:10.1016/0090-4295(92)90009-L.
- Valchanov VD, Michailov P. High energy shock waves in the treatment of delayed and nonunion of fractures. *Int Orthop* 1991. doi:10.1007/BF00192289.
- Tischer T, Milz S, Weiler C, Pautke C, Hausdorf J, Schmitz C. Dose-dependent new bone formation by extracorporeal shock wave application on the intact femur of rabbits. *Eur Surg Res* 2008. doi:10.1159/000128279.
- Schaden W, Fischer A, Sailler A. Extracorporeal shock wave therapy of nonunion or delayed osseous union. *Clin. Orthop. Relat. Res.* 2001. doi:10.1097/00003086-200106000-00012.
- Huang C, Holfeld J, Schaden W, Orgill D, Ogawa R. Mechanotherapy: Revisiting physical therapy and recruiting mechanobiology for a new era in medicine. *Trends Mol Med* 2013. doi:10.1016/j.molmed.2013.05.005.
- Ha CH, Kim S, Chung J, An SH, Kwon K. Extracorporeal shock wave stimulates expression of the angiogenic genes via mechanosensory complex in endothelial cells: Mimetic effect of fluid shear stress in endothelial cells. *Int J Cardiol* 2013. doi:10.1016/j.ijcard.2013.07.112.
- Xu JK, Chen HJ, Li XD, Huang ZL, Xu H, Yang HL. Optimal intensity shock wave promotes the adhesion and migration of rat osteoblasts via integrin β 1-mediated expression of phosphorylated focal adhesion kinase. *J Biol Chem* 2012;287:26200–12. doi:10.1074/jbc.M112.349811.
- Ingber DE. Cellular mechanotransduction: Putting all the pieces together again. *FASEB J* 2006. doi:10.1096/fj.05-5424rev.
- Buarque de Gusmão CV, Batista NA, Vidotto Lemes VT, Maia Neto WL, de Faria LD, Alves JM. Effect of Low-Intensity Pulsed Ultrasound Stimulation, Extracorporeal Shockwaves and Radial Pressure Waves on Akt, BMP-2, ERK-2, FAK and TGF- β 1 During Bone Healing in Rat Tibial Defects. *Ultrasound Med Biol* 2019. doi:10.1016/j.ultrasmedbio.2019.04.011.
- Hu J, Liao H, Ma Z, Chen H, Huang Z, Zhang Y. Focal Adhesion Kinase Signaling Mediated the Enhancement of Osteogenesis of Human Mesenchymal Stem Cells Induced by Extracorporeal Shockwave. *Sci Rep* 2016;6:1–12. doi:10.1038/srep20875.
- Lee FY, Zhen YY, Yuen CM, Fan R, Chen YT, Sheu JJ. The mTOR-FAK mechanotransduction signaling axis for focal adhesion maturation and cell proliferation. *Am J Transl Res* 2017.
- Martini L, Giavaresi G, Fini M, Torricelli P, Borsari V, Giardino R. Shock wave therapy as an innovative technology in skeletal disorder: Study on transmembrane current in stimulated osteoblast-like cells. *Int J Artif Organs* 2005;28:841–7. doi:10.1177/039139880502800810.
- Takahashi T, Nakagawa K, Tada S, Tsukamoto A. Low-energy shock waves evoke intracellular Ca²⁺ increases independently of sonoporation. *Sci Rep* 2019. doi:10.1038/s41598-019-39806-x.
- Chen YJ, Kuo YR, Yang KD, Wang CJ, Chen SMS, Huang HC. Activation of extracellular signal-regulated kinase (ERK) and p38 kinase in shock wave-promoted bone formation of segmental defect in rats. *Bone* 2004;34:466–77. doi:10.1016/j.bone.2003.11.013.
- Wang FS, Wang CJ, Chen YJ, Chang PR, Huang YT, Sun YC. Ras Induction of Superoxide Activates ERK-dependent Angiogenic Transcription Factor HIF-1 α and VEGF-A Expression in Shock Wave-stimulated Osteoblasts. *J Biol Chem* 2004;279:10331–7. doi:10.1074/jbc.M308013200.
- Wang FS, Wang CJ, Huang HJ, Chung H, Chen RF, Yang KD. Physical shock wave mediates membrane hyperpolarization and Ras activation for osteogenesis in human bone marrow stromal cells. *Biochem Biophys Res Commun* 2001. doi:10.1006/bbrc.2001.5654.
- Wang FS, Wang CJ, Sheen-Chen SM, Kuo YR, Chen RF, Yang KD. Superoxide mediates shock wave induction of ERK-dependent osteogenic transcription factor (CBFA1) and mesenchymal cell differentiation toward osteoprogenitors. *J Biol Chem* 2002. doi:10.1074/jbc.M104587200.
- Hsu CC, Cheng JH, Wang CJ, Ko JY, Hsu SL, Hsu TC. Shockwave therapy combined with autologous adipose-derived mesenchymal stem cells is better than with human umbilical cord wharton's jelly-derived mesenchymal stem cells on knee osteoarthritis. *Int J Mol Sci* 2020. doi:10.3390/ijms21041217.
- Yu L, Liu S, Zhao Z, Xia L, Zhang H, Lou J. Extracorporeal Shock Wave Rebuilt Subchondral Bone in Vivo and Activated Wnt5a/Ca2+ Signaling in Vitro. *Biomed Res Int* 2017. doi:10.1155/2017/1404650.
- Tamma R, dell'Endice S, Notarnicola A, Moretti L, Patella S, Patella V. Extracorporeal Shock Waves Stimulate Osteoblast Activities. *Ultrasound Med Biol* 2009. doi:10.1016/j.ultrasmedbio.2009.05.022.
- Hofmann A, Ritz U, Hessmann MH, Alini M, Rommens PM, Rompe JD. Extracorporeal shock wave-mediated changes in proliferation, differentiation, and gene expression of human osteoblasts. *J Trauma - Inj Infect Crit Care* 2008;65:1402–10. doi:10.1097/TA.0b013e318173e7c2.
- Takahashi K, Yamazaki M, Saisu T, Nakajima A, Shimizu S, Mitsuhashi S. Gene Expression for Extracellular Matrix Proteins in Shockwave-Induced Osteogenesis in Rats. *Calcif Tissue Int* 2004. doi:10.1007/s00223-003-0043-3.
- Tam KF, Cheung WH, Lee KM, Qin L, Leung KS. Delayed stimulatory effect of low-intensity shockwaves on human periosteal cells. *Clin Orthop Relat Res* 2005. doi:10.1097/00003086-200509000-00042.
- Tam KF, Cheung WH, Lee KM, Qin L, Leung KS. Osteogenic Effects of Low-Intensity Pulsed Ultrasound, Extracorporeal Shockwaves and Their Combination - An In Vitro Comparative Study on Human Periosteal Cells. *Ultrasound Med Biol* 2008. doi:10.1016/j.ultrasmedbio.2008.06.005.
- Dias Dos Santos PR, De Medeiros VP, Freire Martins de Moura JP, Eduardo da Silveira Franciozi C, Nader HB, Faloppa F. Effects of shock wave therapy on glycosaminoglycan expression during bone healing. *Int J Surg* 2015. doi:10.1016/j.ijsu.2015.09.065.
- Huang HM, Li XL, Tu SQ, Chen XF, Lu CC, Jiang LH. Effects of roughly focused extracorporeal shock waves therapy on the expressions of bone morphogenetic protein-2 and osteoprotegerin in osteoporotic fracture in rats. *Chin Med J (Engl)* 2016;129:2567–75. doi:10.4103/0366-6999.192776.
- Wang FS, Yang KD, Kuo YR, Wang CJ, Sheen-Chen SM, Huang HC. Temporal and spatial expression of bone morphogenetic proteins in extracorporeal shock wave-promoted healing of segmental defect. *Bone* 2003. doi:10.1016/S8756-3282(03)00029-2.
- Chen YJ, Kuo YR, Yang KD, Wang CJ, Huang HC, Wang FS. Shock Wave Application Enhances Pertussis Toxin Protein-Sensitive Bone Formation of Segmental Femoral Defect in Rats. *J Bone Miner Res* 2003. doi:10.1359/jbmr.2003.18.12.2169.
- Iannone F, Moretti B, Notarnicola A, Moretti L, Patella S, Patella V. Extracorporeal shock waves increase interleukin-10 expression by human osteoarthritic and healthy osteoblasts in vitro. *Clin Exp Rheumatol* 2009.
- Sun D, Junger WG, Yuan C, Zhang W, Bao YI, Qin D. Shockwaves induce osteogenic differentiation of human mesenchymal stem cells through ATP release and activation of P2X7 receptors. *Stem Cells* 2013. doi:10.1002/stem.1356.
- Weihl AM, Fuchs C, Teuschl AH, Hartinger J, Slezak P, Mittermayr R. Shock wave treatment enhances cell proliferation and improves wound healing by ATP release-coupled Extracellular signal-regulated Kinase (ERK) activation. *J Biol Chem* 2014. doi:10.1074/jbc.M114.580936.
- Ma Y, Hu Z, Yang D, Li L, Wang L, Xiao J. Extracorporeal cardiac shock waves therapy promotes function of endothelial progenitor cells through PI3K/AKT and MEK/ERK signaling pathways. *Am J Transl Res* 2020.
- Xu L, Zhao Y, Wang M, Song W, Li B, Liu W. Defocused low-energy shock wave activates adipose tissue-derived stem cells in vitro via multiple signaling pathways. *Cytotherapy* 2016;18:1503–14. doi:10.1016/j.jcyt.2016.08.009.
- Hatanaka K, Ito K, Shindo T, Kagaya Y, Ogata T, Eguchi K. Molecular mechanisms of the angiogenic effects of low-energy shock wave therapy: Roles of mechanotransduction. *Am J Physiol - Cell Physiol* 2016;311:C378–85. doi:10.1152/ajpcell.00152.2016.
- Yu W, Shen T, Liu B, Wang S, Li J, Dai D. Cardiac shock wave therapy attenuates H9c2 myoblast apoptosis by activating the AKT signal pathway. *Cell Physiol Biochem* 2014;33:1293–303. doi:10.1159/000358697.

- [36] Zhao Y, Santelli A, Zhu XY, Zhang X, Woollard JR, Chen XJ. Low-Energy Shockwave Treatment Promotes Endothelial Progenitor Cell Homing to the Stenotic Pig Kidney. *Cell Transplant* 2020. doi:10.1177/0963689720917342.
- [37] Wang CJ, Ko JY, Chou WY, Hsu SL, Ko SF, Huang CC. Shockwave therapy improves anterior cruciate ligament reconstruction. *J Surg Res* 2014;188:110-18. doi:10.1016/j.jss.2014.01.050.
- [38] Tepeköylü C, Wang FS, Kozaryn R, Albrecht-Schgoer K, Theurl M, Schaden W. Shock wave treatment induces angiogenesis and mobilizes endogenous CD31/CD34-positive endothelial cells in a hindlimb ischemia model: Implications for angiogenesis and vasculogenesis. *J Thorac Cardiovasc Surg* 2013. doi:10.1016/j.jtcvs.2013.01.017.
- [39] Notarnicola A, Moretti L, Tafuri S, Gigliotti S, Russo S, Musci L. Extracorporeal shockwaves versus surgery in the treatment of pseudoarthrosis of the carpal scaphoid. *Ultrasound Med Biol* 2010;36:1306-13. doi:10.1016/j.ultrasmedbio.2010.05.004.
- [40] Fu M, Sun CK, Lin YC, Wang CJ, Wu CJ, Ko SF. Extracorporeal shock wave therapy reverses ischemia-related left ventricular dysfunction and remodeling: Molecular-cellular and functional assessment. *PLoS One* 2011. doi:10.1371/journal.pone.0024342.
- [41] Schuh CMAP, Heher P, Weihs AM, Banerjee A, Fuchs C, Gabriel C. In vitro extracorporeal shock wave treatment enhances stemness and preserves multipotency of rat and human adipose-derived stem cells. *Cytotherapy* 2014. doi:10.1016/j.jcyt.2014.07.005.
- [42] Sansone V, Brañes M, Romeo P. A novel bimodal approach for treating atrophic bone non-unions with extracorporeal shockwaves and autologous mesenchymal stem cell transplant. *Med Hypotheses* 2018. doi:10.1016/j.mehy.2017.12.013.
- [43] Zhai L, Ma XL, Jiang C, Zhang B, Liu ST, Xing GY. Human autologous mesenchymal stem cells with extracorporeal shock wave therapy for nonunion of long bones. *Indian J Orthop* 2016;50:543-50. doi:10.4103/0019-5413.189602.
- [44] Colbath AC, Kisiday JD, Phillips JN, Goodrich LR. Can Extracorporeal Shockwave Promote Osteogenesis of Equine Bone Marrow-Derived Mesenchymal Stem Cells in Vitro? *Stem Cells Dev* 2020. doi:10.1089/scd.2019.0202.
- [45] Alshihri A, Niu W, Kaemmerer P, Al-Askar M, Yamashita A, Kurisawa M. The effects of shock wave stimulation of mesenchymal stem cells on proliferation, migration, and differentiation in an injectable gelatin matrix for osteogenic regeneration. *J Tissue Eng Regen Med* 2020. doi:10.1002/term.3126.
- [46] Kearney CJ, Hsu HP, Spector M. The use of extracorporeal shock wave-stimulated periosteal cells for orthotopic bone generation. *Tissue Eng - Part A* 2012;18:1500-8. doi:10.1089/ten.tea.2011.0573.
- [47] Wang CJ, Liu HC, Fu TH. The effects of extracorporeal shockwave on acute high-energy long bone fractures of the lower extremity. *Arch Orthop Trauma Surg* 2007;127:137-42. doi:10.1007/s00402-006-0236-0.
- [48] Moretti B, Notarnicola A, Moretti L, Patella S, Tatò I, Patella V. Bone healing induced by ESWT. *Clin Cases Miner Bone Metab* 2009.
- [49] Kieves N, Duerr FM, Palmer RH, Mackay C, Adducci K, Rao S. High Energy Focused Shock Wave Therapy Accelerates Bone Healing: a Blinded, Prospective, Randomized Clinical Trial. *Vet Comp Orthop Traumatol* 2015.
- [50] Chen XF, Huang HM, Li XL, Liu GJ, Zhang H. Slightly focused high-energy shockwave therapy: A potential adjuvant treatment for osteoporotic fracture. *Int J Clin Exp Med* 2015.
- [51] Van Der Jagt OP, Van Der Linden JC, Schaden W, Van Schie HT, Piscaer TM, Verhaar JAN. Unfocused extracorporeal shock wave therapy as potential treatment for osteoporosis. *J Orthop Res* 2009. doi:10.1002/jor.20910.
- [52] Van Der Jagt OP, Piscaer TM, Schaden W, Li J, Kops N, Jahr H. Unfocused extracorporeal shock waves induce anabolic effects in rat bone. *J Bone Jt Surg - Ser A* 2011. doi:10.2106/JBJS.I.01535.
- [53] Van Der Jagt OP, Waarsing JH, Kops N, Schaden W, Jahr H, Verhaar JAN. Unfocused extracorporeal shock waves induce anabolic effects in osteoporotic rats. *J Orthop Res* 2013. doi:10.1002/jor.22258.
- [54] Beutler S, Regel G, Pape HC, Machtens S, Weinberg AM, Kreimeke I. Extracorporeal shock wave therapy for delayed union of long bone fractures-Preliminary results of a prospective cohort study. *J Orthop Trauma* 2000. doi:10.1097/00005131-200003000-00016.
- [55] Ikeda K, Tomita K, Takayama K. Application of extracorporeal shock wave on bone: Preliminary report. *J. Trauma - Inj. Infect. Crit. Care* 1999. doi:10.1097/00005373-199911000-00024.
- [56] Cacchio A, Giordano L, Colafarina O, Rompe JD, Tavernese E, Ioppolo F. Extracorporeal shock-wave therapy compared with surgery for hypertrophic long-bone nonunions. *J Bone Jt Surg - Ser A* 2009;91:2589-97. doi:10.2106/JBJS.H.00841.
- [57] Rompe JD, Rosendahl T, Schöllner C, Theis C. High-energy extracorporeal shock wave treatment of nonunions. *Clin. Orthop. Relat. Res.* 2001. doi:10.1097/00003086-200106000-00014.
- [58] Nada DW, Al Ashkar DS, Abdel Ghany SE, El Khoully RM, El Gebaly OA. Pulsed Electromagnetic Field and Extracorporeal Shock Wave in Treatment of Delayed or Non-United Tibial Fracture, A Comparative Study. *Int J Phys Med Rehabil* 2017. doi:10.4172/2329-9096.1000391.
- [59] Furia JP, Juliano PJ, Wade AM, Schaden W, Mittermayr R. Shock wave therapy compared with intramedullary screw fixation for nonunion of proximal fifth metatarsal metaphyseal-diaphyseal fractures. *J Bone Jt Surg - Ser A* 2010. doi:10.2106/JBJS.I.00653.
- [60] Quadlbauer S, Pezzei C, Beer T, Jurkowsitsch J, Keuchel T, Schlintner C. Treatment of scaphoid waist nonunion by one, two headless compression screws or plate with or without additional extracorporeal shockwave therapy. *Arch Orthop Trauma Surg* 2019. doi:10.1007/s00402-018-3087-6.
- [61] Fallnhauser T, Wilhelm P, Priol A, Windhofer C. Extracorporeal Shockwave Therapy for the treatment of scaphoid delayed union and nonunion: A retrospective analysis examining the rate of consolidation and further outcome variables. *Handchirurgie Mikrochirurgie Plast Chir* 2019. doi:10.1055/a-0914-2963.
- [62] Everding J, Stolberg-Stolberg J, Pützler J, Roßlenbroich S, Ochman S, Raschke M. Extracorporeal shock wave therapy for the treatment of arthrodesis non-unions. *Arch Orthop Trauma Surg* 2020. doi:10.1007/s00402-020-03361-2.
- [63] Zelle BA, Gollwitzer H, Zlowodzki M, Bühren V. Extracorporeal shock wave therapy: Current evidence. *J Orthop Trauma* 2010. doi:10.1097/BOT.0b013e3181cad510.
- [64] Alkhawashki HMI. Shock wave therapy of fracture nonunion. *Injury* 2015. doi:10.1016/j.injury.2015.06.035.
- [65] Haffner N, Antonic V, Smolen D, Slezak P, Schaden W, Mittermayr R. Extracorporeal shockwave therapy (ESWT) ameliorates healing of tibial fracture non-union unresponsive to conventional therapy. *Injury* 2016;47:1506-13. doi:10.1016/j.injury.2016.04.010.
- [66] Vulpiani MC, Vetranò M, Conforti F, Minutolo L, Trischitta D, Furia JP. Effects of extracorporeal shock wave therapy on fracture nonunions. *Am J Orthop (Belle Mead NJ)* 2012;41:E122-7.
- [67] Stojadinovic A, Potter BK, Eberhardt J, Shawen SB, Andersen RC, Forsberg JA. Development of a prognostic naïve Bayesian classifier for successful treatment of nonunions. *J Bone Jt Surg - Ser A* 2011. doi:10.2106/JBJS.I.01649.
- [68] Elster EA, Stojadinovic A, Forsberg J, Shawen S, Andersen RC, Schaden W. Extracorporeal shock wave therapy for nonunion of the tibia. *J Orthop Trauma* 2010. doi:10.1097/BOT.0b013e3181b26470.
- [69] Everding J, Freistühler M, Stolberg-Stolberg J, Raschke MJ, Garcia P. Extracorporele fokussierte Stoßwellentherapie zur Behandlung von Pseudarthrosen: Neue Erfahrungen mit einer alten Technologie. *Unfallchirurg* 2017;120:969-78. doi:10.1007/s00113-016-0238-5.
- [70] Kuo SJ, Su IC, Wang CJ, Ko JY. Extracorporeal shockwave therapy (ESWT) in the treatment of atrophic non-unions of femoral shaft fractures. *Int J Surg* 2015. doi:10.1016/j.ijsu.2015.06.075.