

The Top 10 Reasons Musculoskeletal Sonography Is an Important Complementary or Alternative Technique to MRI

Levon N. Nazarian¹

OBJECTIVE. Worldwide, the use of sonography for the evaluation of the musculoskeletal system has been growing. However, radiologists in North America have been relatively slow to incorporate musculoskeletal sonography into their practices. The purpose of this article is to show the advantages of musculoskeletal sonography.

CONCLUSION. Musculoskeletal sonography is an important complementary tool to MRI and is essential for radiologists who want to provide patients with state-of-the-art musculoskeletal imaging.

Since its introduction in the 1980s, MRI has revolutionized cross-sectional imaging of the musculoskeletal system and has become the most widely used technique for a wide variety of pathologic conditions. The comprehensive depiction of osseous, articular, and soft-tissue pathology provided by MRI is unparalleled. As a result, physicians and surgeons rely heavily on the information provided by MRI to make diagnostic and treatment decisions.

However, while MRI was gaining its ascendancy, another musculoskeletal imaging technique was quietly on the rise—namely, sonography. Rapid improvements in technology have made sonography an important complementary tool for musculoskeletal imaging, and there is now a large body of literature documenting the effectiveness of musculoskeletal sonography. However, whereas the introduction of musculoskeletal MRI revolutionized the way radiology is practiced, musculoskeletal sonography has stayed below the radar of many radiology practices, especially in North America.

Many reasons account for the slow adoption of musculoskeletal sonography into radiology practices. The reason most often cited is its operator dependency. Many radiologists who tend to be insecure about their sonographic scanning skills think that musculoskeletal sonography is too difficult to learn. Radiologists are more comfortable interpreting MR images that are obtained by technologists using standardized protocols. Although proto-

cols also exist for musculoskeletal sonography, the output is generally regarded to be variable and highly dependent on the skill of the examiner. Furthermore, few radiology residency and musculoskeletal fellowship programs offer training in musculoskeletal sonography. Radiologists who are motivated to learn often end up teaching themselves, and must train sonographers to perform the studies because sonographer training programs are similarly lacking in exposure to musculoskeletal sonography. In contradistinction, musculoskeletal MRI is a standard component of radiology residency, musculoskeletal fellowship, and technologist training programs.

Economic barriers to the acceptance of musculoskeletal sonography also exist. It is true that equipment and operating costs are much less for sonography than for MRI. However, professional and technical reimbursements for MRI are much higher. Furthermore, the time a radiologist needs to interpret a musculoskeletal MRI study is often less than for sonography, especially if the radiologist needs to back-scan to confirm the sonographer's findings. Many musculoskeletal MRI studies follow specific protocols and do not require hands-on radiologist supervision. Therefore, radiologists in a busy practice may think that there is much more money to be made from MRI and that musculoskeletal sonography is not worth their time.

Although I certainly understand the difficulties that radiologists may face in implementing musculoskeletal sonography in their practices, there is one interested party who

Keywords: musculoskeletal imaging, sonography

DOI:10.2214/AJR.07.3385

Received November 5, 2007; accepted after revision January 3, 2008.

¹Department of Radiology, Thomas Jefferson University Hospital, Rm. 763E Main Bldg., 132 S 10th St., Philadelphia, PA 19107-5244. Address correspondence to L. N. Nazarian (levon.nazarian@jefferson.edu).

CME

This article is available for CME credit. See www.arrs.org for more information.

AJR 2008; 190:1621–1626

0361-803X/08/1906-1621

© American Roentgen Ray Society

seems to be lost in the shuffle: the patient. If we accept the assumption that radiologists owe it to patients to provide state-of-the-art diagnostic imaging, then we are falling short of this goal when we fail to provide sonography. The fact is, many diagnoses are readily made using musculoskeletal sonography but are either difficult or impossible using MRI. In my practice I have seen countless patients who have suffered with their pain for weeks, months, or even years, undergoing nondiagnostic MRI or other imaging studies, only to have a 20-minute sonographic examination detect the problem and send the patient on the road to recovery. Many of these patients become resentful that the “right” test was not ordered sooner and demand to know why. Patients in chronic pain are not sympathetic to the argument that musculoskeletal sonography is too difficult for radiologists to learn or that it does not pay them well enough.

The purpose of this article is to show the advantages of musculoskeletal sonography for the diagnosis and treatment of musculoskeletal conditions. I have defined scenarios in which sonography is the imaging test of choice over MRI, illustrated by specific examples from my practice. Note that this article is intentionally one-sided: Although there are numerous situations in which MRI is superior to sonography, MRI is already well established and does not need more advocates. Rather, my goal is to convince the reader that patients deserve to be offered musculoskeletal sonography as an imaging option.

So, in no particular order, here are the top 10 reasons that musculoskeletal sonography is an important complementary tool to MRI.

Reason 1: Every Patient Can Undergo Sonography

MRI is relatively contraindicated in patients with cardiac pacemakers and certain metal implants. In addition, many patients cannot complete an MRI examination because of claustrophobia. Open magnets can improve the ability of claustrophobic patients to tolerate MRI, but in a recent study 8.3% of severely claustrophobic patients could not tolerate even an open magnet [1]. No such contraindications exist for sonography; in fact, most patients prefer shoulder sonography to MRI [2]. Patients undergoing sonography can be examined in a more comfortable position and can avoid the prolonged, and sometimes painful, immobilization in the magnet [2]. Nevertheless, many patients for whom sonography is an appropriate op-

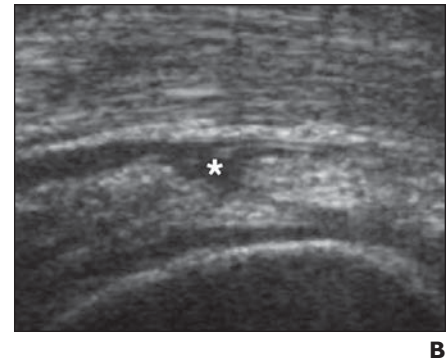
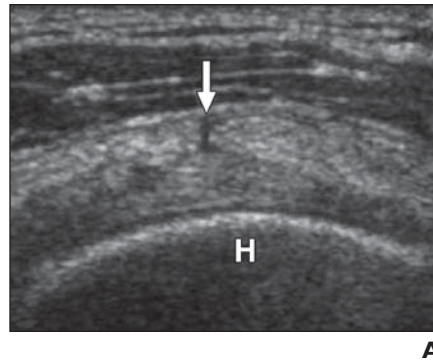


Fig. 1—21-year-old woman, a Division 1 college tennis player with shoulder pain for 1 year. MR arthrogram revealed SLAP (superior labrum anterior to posterior) lesion that was not confirmed at arthroscopy. Capsulorrhaphy was performed with no relief in symptoms. Repeat shoulder MRI was negative. **A**, Short-axis sonogram of supraspinatus tendon reveals linear hypoechoic focus at bursal surface of tendon (arrow). H = humeral head. **B**, Short-axis sonogram of supraspinatus tendon after 5 mL of 0.5% bupivacaine was instilled percutaneously under sonographic guidance into subdeltoid space shows fluid entering bursal-sided supraspinatus tear (asterisk).

tion remain undiagnosed because their referring physicians do not have access to musculoskeletal sonography services.

Reason 2: Sonography Can Resolve Finer Details than MRI

High-frequency sonography can detect tiny abnormalities that simply cannot be shown by standard clinical MRI techniques. The axial resolution of a 10-MHz probe is approximately 150 μm [3], much better than is currently achievable with clinical MRI scanners. For example, a 1.5-T scanner with a field of view of 12 \times 6 cm, a matrix of 256 \times 256 pixels, and a slice thickness of 0.5 cm yields a resolution of 469 \times 469 μm [4]. Because of this superior resolution, common abnormalities such as tendon tears (Fig. 1) are seen more clearly on sonography than on MRI. In addition, sonography can make use of better contrast resolution, because of the differences in acoustic impedance, to detect tiny calcifications (Fig. 2) and foreign bodies (Fig. 3) that cannot be seen on MRI, even on retrospective review of the images.

Reason 3: Sonography Allows Real-Time Dynamic Examination of the Patient

Many musculoskeletal abnormalities are not present when the patient is at rest. A patient may notice pain, clicking, a mass (Fig. 4), or other symptoms that occur only when he or she makes specific movements. Sonography can show in real time the dynamic changes in many conditions such as shoulder impingement syndrome, snapping hip syndrome, peroneal tendon subluxation, tendon gliding abnormalities, and ulnar nerve dislo-

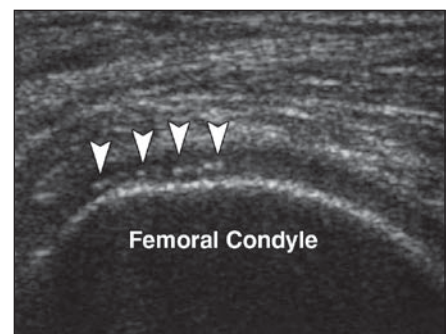


Fig. 2—39-year-old man who had been bothered by knee pain for more than 1 year, especially while riding his bicycle competitively. Knee radiography and MRI were normal. Longitudinal sonogram at level of lateral femoral condyle reveals unsuspected calcification of hyaline cartilage (arrowheads). This area was focally tender to probe pressure, confirming chondrocalcinosis as underlying cause of pain.

cation [5, 6]. Many of these abnormalities simply cannot be shown on static MRI. In addition, dynamic sonography performed during stress can give functional information about ligaments. For example, although both sonography and MRI can depict ulnar collateral ligament tears in the elbow of the throwing athlete, only sonography during valgus stress can directly show the degree of ligamentous laxity, which is important in determining patient management [7] (Fig. 5).

Reason 4: The Ultrasound Probe Can Be Placed Exactly Where It Hurts

Many findings seen on musculoskeletal imaging are asymptomatic, rotator cuff tears being a common example [8]. Without knowing exactly where the patient hurts, it is sometimes

Musculoskeletal Sonography and MRI

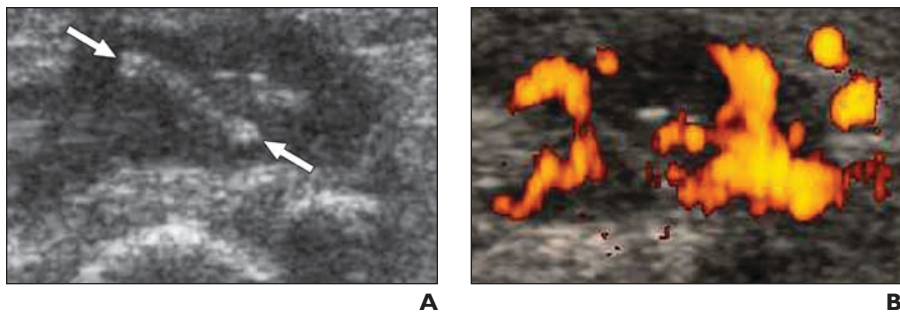


Fig. 3—40-year-old woman who had persistent pain for 2 months after removing rose thorn from her finger after gardening. MRI showed flexor tenosynovitis, for which she was treated with nonsteroidal antiinflammatory medications, with little improvement.

A, Longitudinal sonogram at level of proximal interphalangeal joint of right index finger reveals linear foreign body (between *arrows*) consistent with rose thorn and proven at surgery. Tendon sheath is distended with fluid and debris.

B, Power Doppler sonogram shows marked hyperemia around foreign body, corresponding to tenosynovitis detected on MRI. MRI, however, failed to detect foreign body as underlying problem.

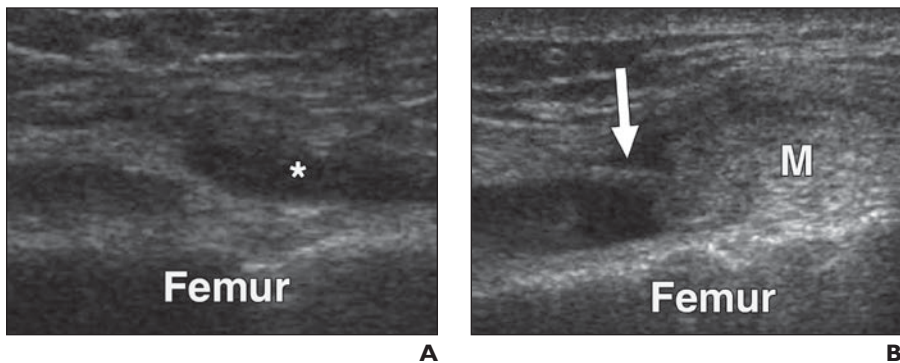


Fig. 4—44-year-old man with painful mass that popped out over his lateral knee with flexion and disappeared with extension. MRI of knee, obtained with knee in extension, failed to find cause of his symptoms.

A, Longitudinal sonogram obtained at lateral aspect of distal femur with knee in extension reveals small amount of fluid (*asterisk*) in lateral recess of joint but no soft-tissue mass.

B, Longitudinal sonogram obtained at lateral aspect of distal femur with knee in flexion reveals approximately 1.5-cm soft-tissue mass (*M*) consistent with fat that abruptly popped into lateral recess of joint, accompanied by pain. At surgery, this mass was shown to be intraarticular fat that was tethered by a plica (*arrow*).

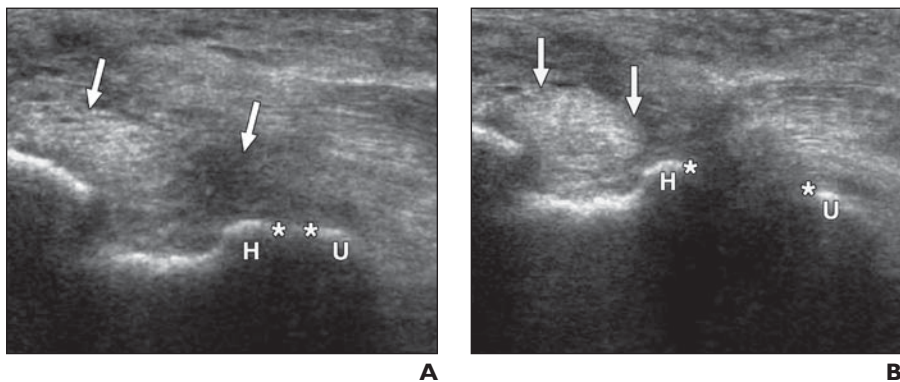


Fig. 5—24-year-old man, competitive javelin thrower, who had a history of ulnar collateral ligament reconstruction 5 years earlier and recently felt a pop and recurrent pain while throwing.

A, Longitudinal sonogram obtained at medial elbow shows heterogeneous, thickened ulnar collateral ligament (*arrows*). At rest, joint space (*asterisks*) between trochlea of humerus (*H*) and coronoid process of ulna (*U*) measures 2.8 mm, which is within normal limits.

B, Longitudinal sonogram obtained at medial elbow with elbow in valgus stress shows marked widening of joint space (*asterisks*) between humerus (*H*) and ulna (*U*), now measuring 11.8 mm. Retraction of ligament (*arrows*) is also accentuated. Findings indicate complete incompetence of reconstructed ulnar collateral ligament. Patient had to undergo repeat ligamentous reconstruction.

difficult for the radiologist interpreting musculoskeletal MRI to prioritize the importance of the imaging findings. Therefore, clinically insignificant findings may be overemphasized, and clinically relevant findings may be overlooked. Placing the ultrasound probe directly over the source of the pain increases the likelihood of detecting the abnormality and ensures that the sonography report will be clinically relevant (Fig. 6). In some cases, the source of pain will actually lie outside the field of view of the MRI, frustrating both patient and physician (Fig. 7).

Reason 5: Sonography Can Effectively Image Patients with Surgical Hardware

Sonography can be used in patients who have orthopedic hardware that causes significant artifact in MRI. So long as the beam does not have to pass through the hardware to reach the soft tissues, the sonographic examination will not be hampered by artifact. For example, sonography can evaluate the rotator cuff in patients who have had shoulder arthroplasty or hemiarthroplasty [9] and can evaluate patients with other types of surgical hardware [10] (Fig. 8). Sonography can depict impingement between orthopedic hardware and soft-tissue structures [11].

Reason 6: Doppler Sonography Gives Important Physiologic Information

Color Doppler sonography and power Doppler sonography are important complements to gray-scale sonography because physiologic information about blood flow can be obtained. When anatomic abnormalities are subtle, detecting increased Doppler flow can increase one's confidence not only that a finding is real but also that it is likely the cause of the patient's pain [12] (Fig. 9). Although hyperemia can also be detected on contrast-enhanced MRI, sonography can provide better resolution of small blood vessels and can define whether these vessels are arterial or venous. Therefore, Doppler sonography is useful in characterizing superficial vascular malformations and soft-tissue masses [13, 14]. Some soft-tissue masses such as neuromas are quite hypoechoic and can simulate cysts on sonography, and the presence of internal Doppler flow can confirm their solid nature [15]. Color Doppler sonography and power Doppler sonography are also effective in characterizing rheumatoid and other inflammatory arthritides [16], bursitis [17], painful tendinopathies [18], foreign bodies [19] (Fig. 3B), infections [20], and other soft-tissue inflammatory processes [21] (Fig. 10).

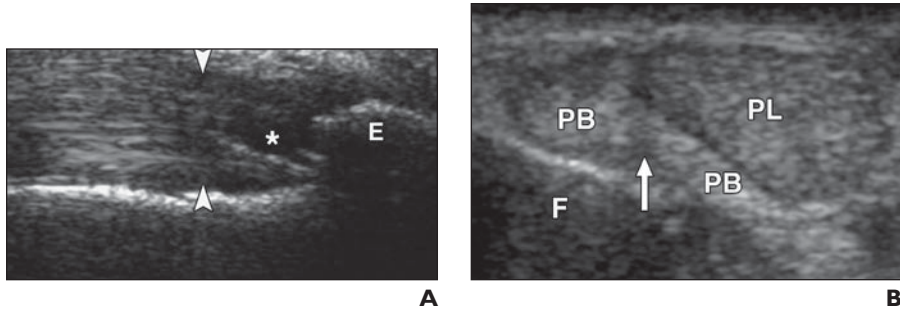


Fig. 6—68-year-old man, runner in Senior Olympics, has been experiencing ankle pain. Sonography was ordered to “rule out Achilles tendon tear.”
A, Longitudinal sonogram of Achilles tendon (*arrowheads*) shows thickened tendon with hypoechoic focus (*asterisk*) and calcaneal enthesophyte (E), consistent with Achilles tendinosis. However, during examination, patient asked, “Doc, why are you scanning there? That’s not where it hurts.”
B, Axial sonogram obtained at area of pain identified by patient reveals thickened, tendinotic peroneus longus (PL) and split tear of peroneus brevis (PB, *arrow*) at level of distal fibula (F). Knowing where patient hurt enabled radiologist to produce a more clinically relevant report. Sonography also directed therapy to appropriate tendons.

Reason 7: Sonography Is Better for Differentiating Fluid from Solid Material

One of the strengths of sonography is in differentiating cystic from solid lesions. It is not unusual for a diagnosis based on MRI to indicate a cyst or other fluid collection because of the bright signal on T2-weighted images, only to have sonography show unsuspected internal complexity. For example, joint effusions, postoperative collections, Baker cysts, parameniscal cysts, paralabral cysts, and ganglion cysts all may appear amenable to percutaneous aspiration on MRI, but sonography may show that they are in fact filled with thick debris or vascularized synovial tissue as depicted by color or power Doppler sonography (Fig. 10).

Reason 8: Sonography Is Better for Guiding Therapeutic Interventions

The real-time capability of sonography gives it a clear advantage over MRI in guiding a wide range of musculoskeletal interventions because the needle can reach its intended target while avoiding major blood vessels and nerves [22]. The nature of soft-tissue masses can be diagnosed with either fine-needle aspiration or core biopsy. Sonography facilitates

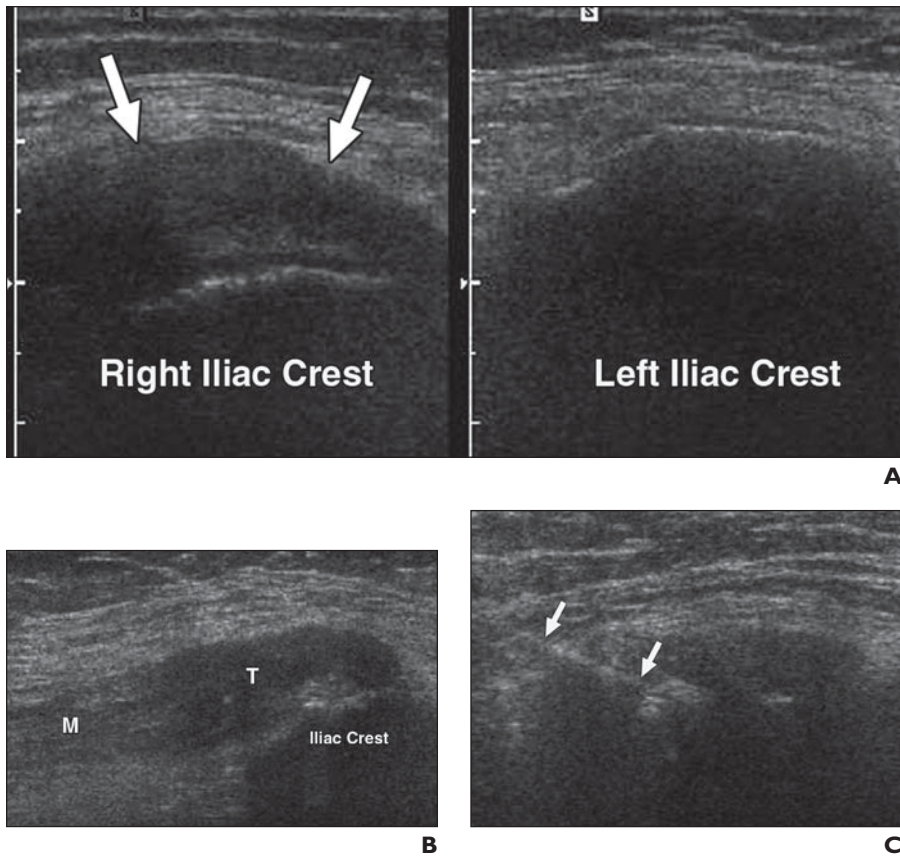


Fig. 7—46-year-old woman with 2 years of severe, progressively increasing right “hip” pain. During that time she had undergone two hip MRI examinations and one lumbosacral spine MRI examination, all of which failed to detect cause of pain. In retrospect, none of the MRI examinations included actual source of pain in their field of view.
A, Axial sonogram was obtained over area of most severe tenderness—right iliac crest—with image of left iliac crest included for comparison. Thickened hypoechoic structure (*arrows*) was identified on right that was not present on left.
B, Longitudinal extended-field-of-view sonogram at right iliac crest shows right external oblique muscle (M) and tendon (T). Hypoechoic structure seen in **A** is a thickened and calcified external oblique tendon. This tendinosis likely resulted from repeatedly twisting her torso during her 18 years as a professional blackjack dealer.
C, Under local anesthetic and sonographic guidance, 18-gauge spinal needle (*arrows*) was inserted to fenestrate tendon and break up calcifications. Within 8 weeks after procedure, pain had completely resolved.

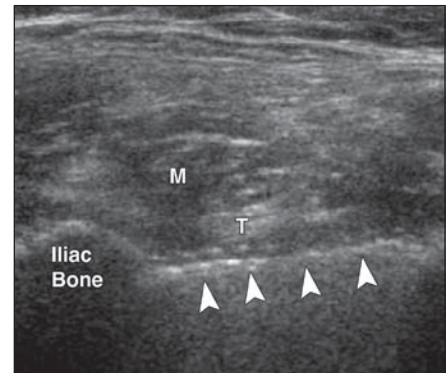


Fig. 8—29-year-old woman with severe, unrelenting stabbing pain in right hip. Her pain became significantly worse after osteotomy surgery 2 years previously for hip dysplasia. Numerous imaging studies, including MRI, were unrevealing. Musculoskeletal sonography was not available in her region, so she flew from Portland, OR, to Philadelphia, PA, to be examined. Her orthopedic surgeon provided a prescription for sonography but told me, “You won’t find anything; that patient is crazy.” Axial sonogram at level of iliopsoas muscle (M) shows surgical screw (*arrowheads*) that has pierced iliac bone and lies deep in relation to iliopsoas tendon (T). Dynamic images (not shown) showed that whenever patient flexed her hip, tendon rubbed against the screw, reproducing her excruciating pain. Screw was surgically removed (by a different orthopedic surgeon), and her stabbing pain immediately resolved.

Downloaded from www.ajronline.org by Vrije Universiteit De Boelelaan 1095 on 12/09/13 from IP address 130.37.129.78. Copyright ARRS. For personal use only; all rights reserved.

Musculoskeletal Sonography and MRI

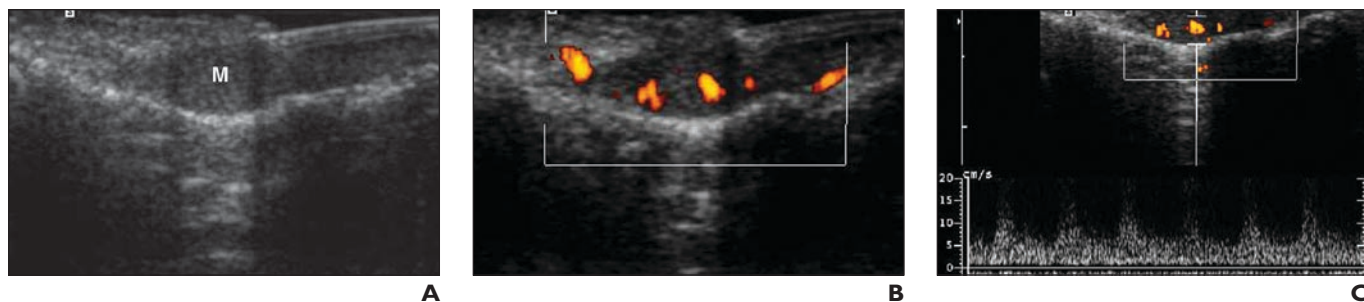


Fig. 9—40-year-old woman with thumb pain. MRI was nondiagnostic.

A, Longitudinal sonogram of nail bed shows subtle hypoechoic mass (M).

B, Power Doppler sonogram of mass shows internal flow.

C, Spectral Doppler waveforms confirm presence of arterial flow. Glomus tumor was diagnosed and confirmed at surgery.

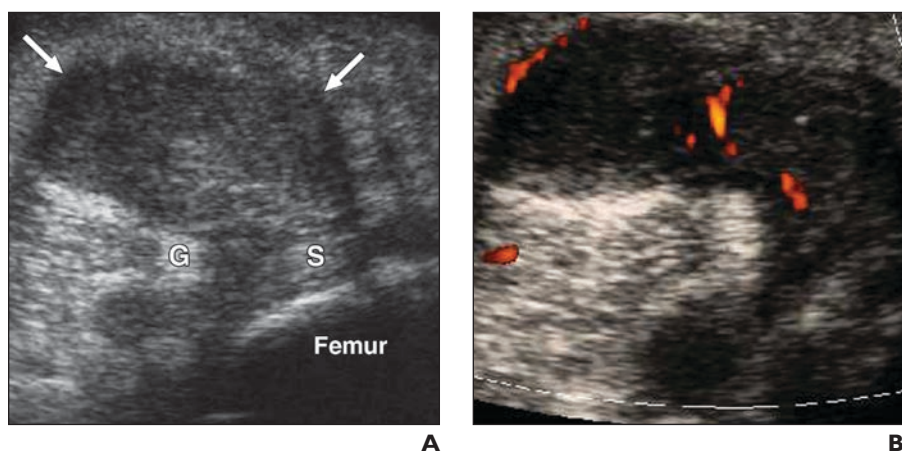


Fig. 10—64-year-old woman with rheumatoid arthritis and posterior knee pain. MRI showed Baker cyst, and patient was referred for sonographically guided aspiration.

A, Axial sonogram obtained at medial popliteal fossa shows that Baker cyst (arrows) is completely filled with solid material. This finding was not apparent on MRI because Baker cyst was homogeneously hyperintense on T2-weighted images. Note characteristic location between medial head of gastrocnemius (G) and semimembranosus (S) tendons.

B, Power Doppler sonogram shows some internal vascularity in Baker cyst, consistent with rheumatoid pannus. Under sonographic guidance, pannus was injected with corticosteroid for symptomatic relief.

aspiration of joints, bursae, and cysts by precisely guiding the needle into drainable fluid pockets, thereby allowing patients to be spared painful “dry taps.” Sonographically guided therapeutic injections of corticosteroids or other medications can be performed of joints, bursae, or tendon sheaths [22]. Sonography also provides guidance for more innovative treatments such as autologous blood injections, percutaneous needle tenotomy with or without lavage of calcifications (Fig. 7C), or sclerosis of neovessels to treat tendinosis [23–26]. From a patient’s standpoint, sonography provides a unique opportunity to both diagnose and treat in one session. A patient can arrive in the ultrasound department in pain, have the diagnosis made, and by virtue of a sonographically guided intervention, leave the department already on the road to

recovery. Such “one-stop shopping” is more difficult to achieve with MRI.

Reason 9: Sonography Facilitates Bilateral Comparison

A wide degree of anatomic variability exists in the musculoskeletal system. Consequently, detecting bilateral asymmetry can be useful in deciding whether an abnormality is present. For example, tendon thicknesses can vary depending on body habitus, so that when a tendon measurement is obtained, it may be difficult to assess whether the tendon is abnormally thickened. On sonography it is an easy matter to lift the probe and place it on the contralateral side to obtain a comparison image. Of course, there is a potential pitfall: The examiner has to keep in mind that musculoskeletal abnormalities may be bilateral even if the symptoms are unilateral [8, 27].

Reason 10: Sonography Has a More Flexible Field of View

One of the advantages of MRI is that, for a given anatomic segment, it has a more comprehensive field of view than sonography does. However, this advantage is somewhat offset by the ability of the ultrasound probe to be moved readily from one anatomic segment to another. Therefore, sonography is the preferred imaging test for structures that have a long course in the body, such as peripheral nerves. For example, if a patient has an ulnar neuropathy with equivocal findings on electromyography, the ulnar nerve can be traced throughout the upper extremity, and common sites of compressive neuropathy such as the cubital tunnel and Guyon’s canal can be imaged in rapid succession [28].

Conclusion

Although MRI remains the imaging reference standard for a wide range of musculoskeletal disorders, musculoskeletal sonography is an important complementary, and in some cases alternative, technique to MRI. In many instances sonography should be the test of choice on the basis of the advantages that I have discussed here. Radiologists need to embrace musculoskeletal sonography so that their patients can reap the benefits. Admittedly, difficulties exist in learning any new technique, especially one as operator-dependent as sonography. However, having been present at the birth of musculoskeletal MRI, I can attest that the learning curve at that time was also quite steep. I recall working as a resident with a renowned musculoskeletal radiologist while she was officially reviewing the first knee MRI ever performed at our institution. I was instructed to “read the MR image just like a radiograph.” We have come a long way since then in our MRI interpretive skills, owing to more advanced training

in MRI interpretation. The same process needs to occur for musculoskeletal sonography, with greater training in the performance and interpretation of musculoskeletal sonography in radiology residency and fellowship programs. Not only will the patients benefit, but the radiologist will also gain the immense satisfaction that results from directly interacting with a patient, making a diagnosis that has heretofore been elusive, and, in some cases, performing a therapeutic intervention that alleviates the pain. Musculoskeletal sonography is indeed a uniquely rewarding field.

References

1. Bangard C, Paszek J, Berg F, et al. MR imaging of claustrophobic patients in an open 1.0T scanner: motion artifacts and patient acceptability compared with closed bore magnets. *Eur J Radiol* 2007; 64:152–157
2. Middleton WD, Payne WT, Teeffey SA, Hildebolt CF, Rubin DA, Yamaguchi K. Sonography and MRI of the shoulder: comparison of patient satisfaction. *AJR* 2004; 183:1449–1452
3. Neumann T, Erment H. Schlieren visualization of ultrasonic wave fields with high spatial resolution. *Ultrasonics* 2006; 44[suppl 1]:e1561–e1566
4. Link TM, Majumdar S, Peterfy C, et al. High resolution MRI of small joints: impact of spatial resolution on diagnostic performance and SNR. *Magn Reson Imaging* 1998; 16:147–155
5. Khoury V, Cardinal E, Bureau NJ. Musculoskeletal sonography: a dynamic tool for usual and unusual disorders. *AJR* 2007; 188:203; [web]W63–W73
6. Neustadter J, Raikin SM, Nazarian LN. Dynamic sonographic evaluation of peroneal tendon subluxation. *AJR* 2004; 183:985–988
7. DeSmet AA, Winter TC, Best TM, Bernhardt DT. Dynamic sonography with valgus stress to assess elbow ulnar collateral ligament injury in baseball pitchers. *Skeletal Radiol* 2002; 31:671–676
8. Yamaguchi K, Ditsios K, Middleton WD, Hildebolt CF, Galatz LM, Teeffey SA. The demographic and morphological features of rotator cuff disease: a comparison of asymptomatic and symptomatic shoulders. *J Bone Joint Surg Am* 2006; 88:1699–1704
9. Sofka CM, Adler RS. Sonographic evaluation of shoulder arthroplasty. *AJR* 2003; 180:1117–1120
10. Jacobson JA, Lax MJ. Musculoskeletal sonography of the postoperative orthopedic patient. *Semin Musculoskelet Radiol* 2002; 6:67–77
11. Shetty M, Fessell DP, Femino JE, Jacobson JA, Lin J, Jamadar D. Sonography of ankle tendon impingement with surgical correlation. *AJR* 2002; 179:949–953
12. Zanetti M, Metzdorf A, Kundert HP, et al. Achilles tendons: clinical relevance of neovascularization diagnosed with power Doppler US. *Radiology* 2003; 227:556–560
13. Gold L, Nazarian LN, Johar AS, Rao VM. Characterization of maxillofacial soft tissue vascular anomalies by ultrasound and color Doppler imaging: an adjuvant to CT and MR. *J Oral Maxillofac Surg* 2003; 61:19–31
14. Bodner G, Schocke MFH, Rachbauer F, et al. Differentiation of malignant and benign musculoskeletal tumors: combined color and power Doppler US and spectral wave analysis. *Radiology* 2002; 223:410–416
15. Reynolds DL, Jacobson JA, Inampudi P, Jamadar DA, Ebrahim FS, Hayes CW. Sonographic characteristics of peripheral nerve sheath tumors. *AJR* 2004; 182:741–744
16. Weidekamm C, Koller M, Weber M, Kainberger F. Diagnostic value of high-resolution B-mode and Doppler sonography for imaging of hand and finger joints in rheumatoid arthritis. *Arthritis Rheum* 2003; 48:325–333
17. Newman JS, Adler RS, Bude RO, Rubin JM. Detection of soft tissue hyperemia: value of power Doppler sonography. *AJR* 1994; 163:385–389
18. Reiter M, Ulreich N, Dirisamer A, Tscholakoff D, Bueck RA. Colour and power Doppler sonography in symptomatic Achilles tendon disease. *Int J Sports Med* 2004; 25:301–305
19. Davae KC, Sofka CM, DiCarlo E, Adler RS. Value of power Doppler imaging and the hypoechoic halo in the sonographic detection of foreign bodies: correlation with histopathologic findings. *J Ultrasound Med* 2003; 22:1309–1313
20. Bureau NJ, Chhem RK, Cardinal E. Musculoskeletal infections: US manifestations. *RadioGraphics* 1999; 19:1585–1592
21. Nazarian LN, Schweitzer ME, Mandel SM, et al. Increased soft-tissue blood flow in patients with reflex sympathetic dystrophy of the lower extremity revealed by power Doppler sonography. *AJR* 1998; 171:1245–1250
22. Joines MM, Motamedi K, Seeger L, DiFiori JP. Musculoskeletal interventional ultrasound. *Semin Musculoskelet Radiol* 2007; 11:192–198
23. McShane JM, Nazarian LN, Harwood MI. US-guided percutaneous needle tenotomy for treatment of common extensor tendinosis in the elbow. *J Ultrasound Med* 2006; 25:1281–1289
24. del Cura JL, Torre I, Zabala R, Legórburu A. Sonographically guided percutaneous needle lavage in calcific tendinitis of the shoulder: short- and long-term results. *AJR* 2007; 189:566; [web] W128–W134
25. Connell DA, Ali KE, Ahmad M, Lambert S, Corbett S, Curtis M. Ultrasound-guided autologous blood injection for tennis elbow. *Skeletal Radiol* 2006; 35:371–377
26. Hoskrud A, Ohberg L, Alfredson H, Bahr R. Ultrasound-guided sclerosis of neovessels in painful chronic patellar tendinopathy: a randomized controlled trial. *Am J Sports Med* 2006; 34:1738–1746
27. Levin D, Nazarian LN, Miller TT, et al. Sonographic detection of lateral epicondylitis of the elbow. *Radiology* 2005; 237:230–234
28. Martinoli C, Bianchi S, Gandolfo N, Valle M, Simonetti S, Derchi LE. US of nerve entrapments in osteofibrous tunnels of the upper and lower limbs. *RadioGraphics* 2000; 20:S199–S213

FOR YOUR INFORMATION

This article is available for CME credit. See www.arrs.org for more information.