Journal of Orthopaedic Science xxx (xxxx) xxx

Contents lists available at ScienceDirect

Journal of Orthopaedic Science

journal homepage: http://www.elsevier.com/locate/jos

Original Article

Ultrasound findings of the deltoid ligament in patients with acute ankle sprains: A retrospective review

Toru Omodani [a, b, *], Kenji Takahashi [a]

[a] Sports Medicine & Joint Center, Funabashi Orthopaedic Hospital, 1-833, Hasama-cho, Funabashi, Chiba Prefecture 2740822, Japan
[b] Department of Physical Medicine and Rehabilitation, University of Pittsburgh School of Medicine, Pittsburgh, PA 15213, USA

ARTICLE INFO

Article history:
Received 15 February 2022
Received in revised form
31 March 2022
Accepted 11 May 2022
Available online xxx

Keywords:
Deltoid ligament
Ankle sprain
Ultrasound
Sonography
Medial ankle pain
Trauma

ABSTRACT

Background: The deltoid ligament is a complex structure composed of multiple ligaments located on the medial side of the ankle joint that can be injured by ankle sprains. Although there have been previous reports on ultrasound imaging of the injured deltoid ligament, a systematic method for depicting each ligament component has not been established. This study aimed to clarify the ultrasound findings of the deltoid ligament in ankle sprains using a systematic scanning protocol.
Methods: We examined the tenderness of the medial ankle and evaluated the ultrasound findings of the deltoid ligament in 169 sprained ankles with no fracture, within 3 days after injury. Observation and evaluation of the six components of the deltoid ligament were performed using a systematic scanning protocol with four probe positions.
Results: Of the 169 ankles, 48 ankles had tenderness in the deltoid ligament. Ultrasonography confirmed deltoid ligament damage in 13 of these 48 ankles. Of the 13 ankles, 3 ankles had damages only in the superficial layer, 3 ankles only in the deep layer, and 7 ankles in both the superficial and deep layers.
Conclusions: We clarified the details of the damage pattern of the deltoid ligament in acute ankle sprains. It was possible to identify the superficial and deep layers of the ligament and to observe the damage pattern of each ligament component in detail, and it appeared that ultrasonography could be used as a tool to evaluate the damage pattern of the deltoid ligament in acute ankle sprains.

1. Introduction

The deltoid ligament is a complex structure composed of multiple ligaments located on the medial side of the ankle joint [1]. The deltoid ligament is composed of superficial and deep components, each of which has multiple ligamentous components [1,2]. The superficial layer includes the tibionavicular ligament (TNL), tibiospring ligament (TSL), tibiocalcaneal ligament (TCL), and superficial posterior tibiotalar ligament (SPTL) [1]. The deep layer includes the deep anterior tibiotalar ligament (DATL) and deep posterior tibiotalar ligament (DPTL) [1] (Fig. 1).

Ankle sprains are the most common type of injury in the sports population, account for a high percentage of all injuries [3–5]. Although deltoid ligament injuries are not as common as lateral ligament injuries in ankle sprains, they cause time loss and disability [6,7].

There have been several reports on the ultrasound scanning of the deltoid ligament, including both normal and injured [8–17]. However, the position of the probe for scanning the deltoid ligament has not been systematized; therefore, ultrasound findings of the deltoid ligament seem to be inconsistent from report to report. This study, therefore, aimed to clarify the details of the ultrasound findings of the injury morphology of the deltoid ligament in acute ankle sprains using a systematic scanning protocol.

2. Materials and methods

Overall, 310 patients (310 ankles) visited the authors' outpatient clinic between April 2018 and April 2021 with a chief complaint of ankle pain caused by ankle sprain. The patients' mean age was 23

Abbreviations: TNL, tibionavicular ligament; TSL, tibiospringligament; TCL, tibiocalcanealligament; SPTL, superficial posterior tibiotalar ligament; DATL, deep anterior tibiotalar ligament; aDPTL, anterior section of the deep posterior tibiotalar ligament; pDPTL, posterior section of the deep posterior tibiotalar ligament.

* Corresponding author. Department of Physical Medicine and Rehabilitation, University of Pittsburgh School of Medicine, Pittsburgh, PA 15213, USA. Fax: +1-474-256-592.
E-mail address: t0ru0m0dani@gmail.com (T. Omodani).

https://doi.org/10.1016/j.jos.2022.05.010

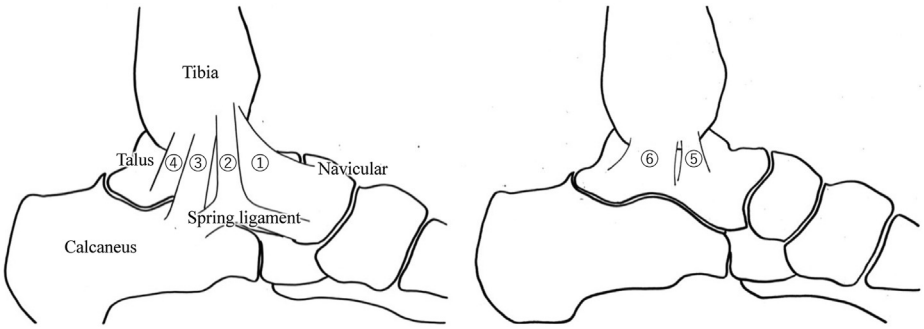

Fig. 1. The deltoid ligament components. The superficial layer: (1) the tibionavicular ligament, (2) tibiospring ligament, (3) tibiocalcaneal ligament, and (4) superficial posterior tibiotalar ligament. The deep layer: (5) the deep anterior tibiotalar ligament and (6) deep posterior tibiotalar ligament.

(range 5–87) years, and the mean time between injury and consultation was 8 (range 0–56) days. The mechanisms of ankle sprain according to patient reports were supination sprain in 169 patients, pronation sprain in 30 patients, and unknown in 111 patients.

Of the 310 patients, 10 patients who were promptly operated on for ankle fracture and 131 patients with a time interval between injury and consultation of more than 4 days were excluded. A retrospective review of medical records and ultrasonographic findings was performed on the remaining 169 patients (169 ankles) who did not have fractures and were examined within 3 days of injury.

2.1. Tenderness of the deltoid ligament

To evaluate the medial ankle pain, the deltoid ligament was considered painful if tenderness was observed in any part of the area bounded by the anterior and posterior colliculus of the medial malleolus, tubercle of the navicular, sustentaculum tali of the calcaneus, and posteromedial talar tubercle (Fig. 2).

2.2. Ultrasonographic scanning method

For ultrasound evaluation of the deltoid ligament, the location and size of the attachment of each ligament were determined according to the report by Campbell et al. [1] Because the DPTL is the broadest ligament with the largest area of attachment on both the tibial and talar sides among all the components [1], the DPTL was divided into anterior and posterior sections for ultrasonographic scans. Ultrasound examinations were performed with the ankle in a neutral position except for the most posterior scanning area. The systematic scanning method for each ligament component is as follows:

1. **Tibionavicular ligament**

The probe was placed on the line connecting the anterior colliculus of the medial malleolus to the slightly dorsal aspect of the navicular tubercle in order to depict the ligamentous component from the surface of the medial malleolus to the navicular tubercle (Fig. 3A and B).

2. **Tibiospring ligament and deep anterior tibiotalar ligament**

The probe was placed on the line connecting the anterior colliculus and the sustentaculum tali of the calcaneus, and the calcaneal side of the probe was rotated in the distal direction using the tibial side of the probe as the fulcrum. The width of rotation should be one-third of the distance between the sustentaculum tali of the calcaneus and the tubercle of the navicular. The TSL, which starts from the surface of the medial malleolus, passes over the talus, and stops at the spring ligament instead of the bone, can be visualized. In the deep layer of the TSL, the DATL from the medial malleolus to the talus can be seen (Fig. 3C and D).

3. **Tibiocalcaneal ligament and anterior section of the deep posterior tibiotalar ligament**

The probe was placed on the line connecting the anterior colliculus of the medial malleolus and the sustentaculum tali of the calcaneus. The TCL, which starts from the surface of the medial malleolus and stops at the sustentaculum tali, was visualized. Anterior section of the deep posterior tibiotalar ligament (aDPTL)

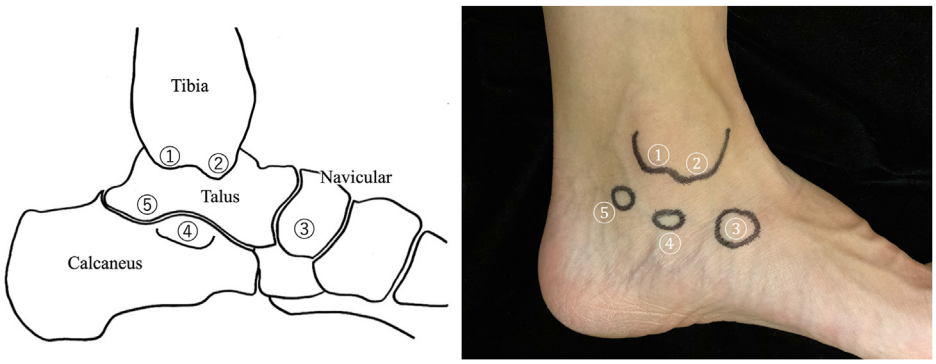

Fig. 2. Bony landmarks. (1) Posterior colliculus of the medial malleolus, (2) anterior colliculus of the medial malleolus, (3) tubercle of the navicular, (4) sustentaculum tali of the calcaneus, and (5) posteromedial talar tubercle.

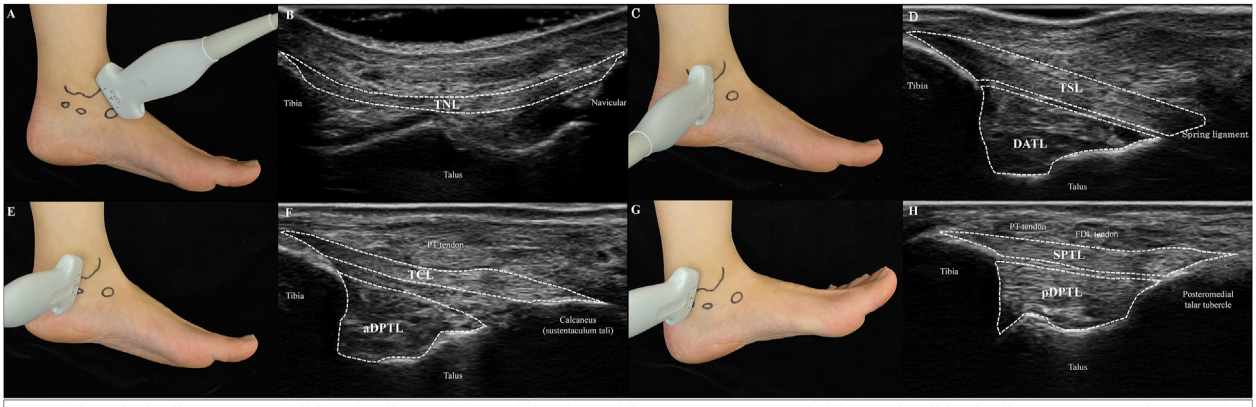

TNL: tibionavicular ligament, TSL: tibiospring ligament, TCL: tibiocalcaneal ligament, SPTL: superficial posterior tibiotalar ligament, DATL: deep anterior tibiotalar ligament, aDPTL: anterior section of the deep posterior tibiotalar ligament, pDPTL: posterior section of the deep posterior tibiotalar ligament.

Fig. 3. Probe positions and ultrasound findings. (A,B) Tibionavicular ligament. (C,D) Tibiospring ligament and deep anterior tibiotalar ligament. (E,F) Tibiocalcaneal ligament and anterior section of deep posterior tibiotalar ligament. (G,H) Superficial posterior tibiotalar ligament and posterior section of the deep posterior tibiotalar ligament.

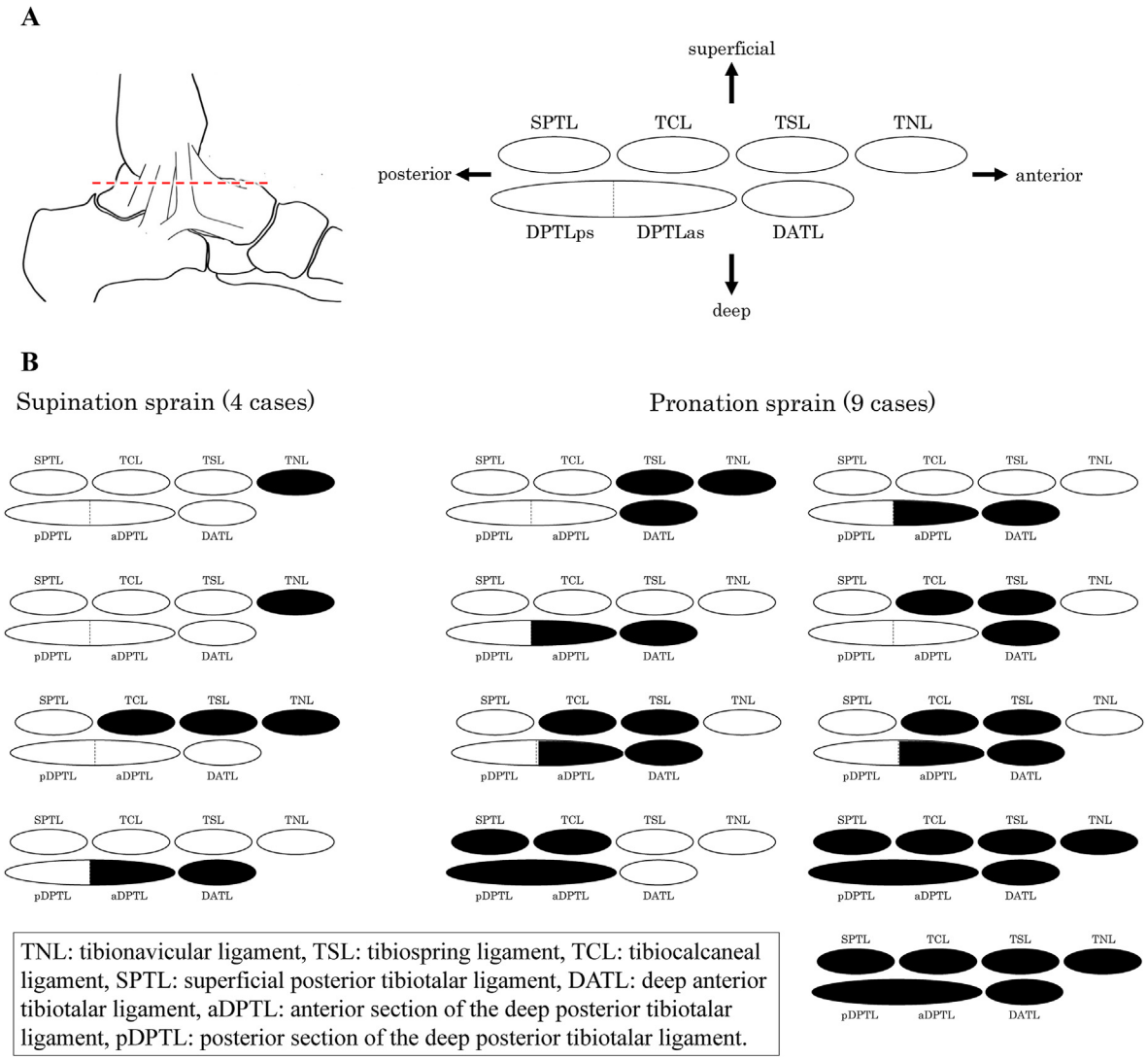

TNL: tibionavicular ligament, TSL: tibiospring ligament, TCL: tibiocalcaneal ligament, SPTL: superficial posterior tibiotalar ligament, DATL: deep anterior tibiotalar ligament, aDPTL: anterior section of the deep posterior tibiotalar ligament, pDPTL: posterior section of the deep posterior tibiotalar ligament.

Fig. 4. (A) Schematic diagram of the cross-sectional view of the deltoid ligament. (B) The ellipses filled in black indicate a damaged ligament component and white indicate a normal ligament.

from the medial malleolus to the talus was also visualized in the deep layer (Fig. 3E and F).

4. **Superficial posterior tibiotalar ligament and posterior section of the deep posterior tibiotalar ligament**

The probe was placed on the line connecting the posterior colliculus of the medial malleolus and the posteromedial talar tubercle. In the neutral position, the ligament is loosened [18] and the ligamentous portion is hypoechoic on the ultrasound image. The probe was therefore placed in the dorsiflexed ankle position to ensure the pain was tolerable and to tense the ligament and increase its visibility in the ultrasound image. The SPTL, starting from the shallow part of the posterior colliculus and stopping at the posteromedial talar tubercle, and the posterior section of the deep posterior tibiotalar ligament (pDPTL) from the deep part of the posterior colliculus to the rising part of the posteromedial talar tubercle were visualized (Fig. 3G and H).

The results of the ultrasound findings described above were reviewed in cases with tenderness in the deltoid ligament. The ultrasound findings of the deltoid ligament with loss of fibrillar pattern or disruption of ligamentous structures were considered ligamentous injuries [8].

Evaluation of tenderness, ultrasonography, and image reading were performed by an orthopedic surgeon with more than 5 years of experience in musculoskeletal ultrasonography. The ultrasound equipment used in this study was a SONIMAGE HS1 with a linear probe L11-3 (Konica Minolta, Tokyo, Japan). This study was conducted with the consent of all patients and relevant persons in accordance with the Declaration of Helsinki, and approved by the ethics committee to which the authors belong.

3. Results

Of the 169 ankles that did not show ankle fractures and were examined within 3 days of injury, 48 ankles showed tenderness in the deltoid ligament area. Of these 48 ankles, there were 13 ankles with ultrasound findings indicating damage to the deltoid ligament, 4 with supination sprains, and 9 with pronation sprains.

Of the 13 ankles, 3 ankles had damages only in the superficial layer, 3 ankles only in the deep layer, and 7 ankles in both the superficial and deep layers (Fig. 4). Ultrasound images of representative cases are shown in Fig. 5.

4. Discussion

In this study, we investigated the details of the ultrasound findings of the injury morphology of the deltoid ligament in acute ankle sprains using a systematic scanning protocol. Of the 169 ankle sprains examined within 3 days of injury, 13 cases had abnormal ultrasound findings of the deltoid ligament and were considered to be injured. In 3 of the 13 ankle sprains, only the deep component was injured without any damage to the superficial layer.

The systematic scanning protocol for the deltoid ligament used in this study was based on four probe positions focusing on bony landmarks on the medial side of the ankle to delineate each ligament component. Several previous studies have reported on ultrasound imaging of the deltoid ligament [8–17]. However, many of them did not seem to have sufficient details on how to position the probe or which ligament components were depicted. Hung et al. and Omodani presented high-resolution ultrasound images of a normal deltoid ligament with four probe positions [19,20]. On the other hand, this study is unique in that the angle and position of the probe in relation to the medial side of the ankle are clearly shown using a diagram, and ultrasound images of the cases with ankle sprains are presented.

Of the 169 ankle sprains examined within 3 days of injury, 13 (8%) showed abnormal ultrasound findings of the deltoid ligament and were considered to be injured. The first 3 days after the occurrence of a ligament injury constitute an inflammatory phase which is followed by a proliferative phase [21]. Therefore, by including only patients examined within 3 days after injury, we were able to observe the state of injury before the ligament healed. The evaluation of the deltoid ligament injury using ultrasound for ankle trauma has been reported in ankle fractures [12,15,16]. Rosa et al. performed ultrasonography on 81 ankles with lateral malleolus fractures and reported that 64 ankles (79.0%) showed damage to the deltoid ligament [16]. The lower prevalence of the deltoid ligament injuries in this study compared with that in the previous study may be due to the exclusion of fracture cases from our study. The lateral malleolus is considered to be one of the important factors that stabilize the talus motion [22]. Because the lateral malleolus was preserved in the subjects of this study, there would be relatively little movement of the talus associated with the sprain, which may have resulted in fewer cases of injury to the deltoid ligament.

In 3 of the 13 ankles with deltoid ligament injuries, only the deep layer of the ligament was injured without any damage to the superficial layer. Previous studies have reported that there are pathologies in which only the deep layer of the deltoid ligament is damaged [23–25]. Jeong et al. reported that, in magnetic resonance imaging (MRI) findings of 36 ankles with trauma including fracture, 4 ankles (11.1%) showed only deep layer injury of the deltoid ligament [23]. From this study, it was found that ultrasound images can also identify damage only in the deep component.

There are several limitations to this study. First, the findings of the ultrasound images were not compared with other imaging modalities, such as MRI or arthroscopy, and the determination of ligamentous injury was based solely on the B-mode ultrasound findings. The stressed dynamic scanning and Doppler ultrasound images were not evaluated. Furthermore, the possibility that chronic ligament injury due to a past ankle sprain could have been detected by ultrasonography was not considered. Second, because we did not compare the ultrasound scanning method presented here with other methods, we were unable to show that this method is particularly useful for deltoid ligament delineation. In particular, the TNL was scanned with the ligament loosened in the neutral position, a method that may have included the risk of misidentifying a hypoechoic area as a ligament injury owing to ultrasound anisotropy. In future, we would like to consider scanning the TNL in the plantar flexion position with tension applied to the ligament. Third, complications with other ligament injuries, such as the anterior talofibular ligament and the syndesmosis injury, have not been studied, and only the injury morphology of the deltoid ligament has been focused on. Finally, other limitations include the fact that the scanning was performed and the image were read by a single examiner, and that it was a retrospective study conducted at a single institution. Despite the above limitations, this study may contribute to the establishment of ultrasound evaluation methods for the deltoid ligament in the future, because it illustrated in detail the scanning method and clarified ligament components that are depicted in ultrasound evaluation, including normal and injured ankles. Further studies are needed to demonstrate the validity of the delineation method presented in this study.

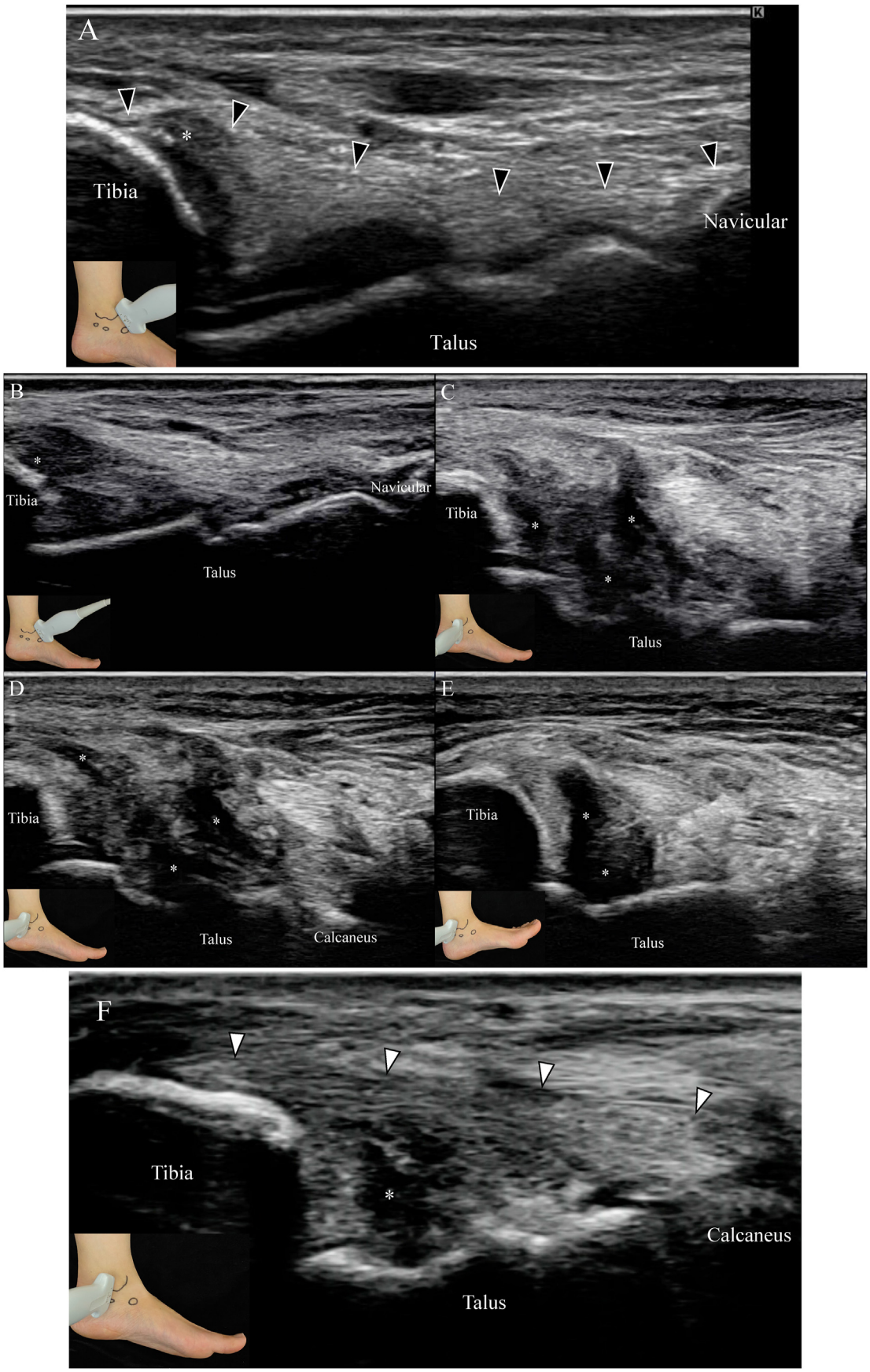

Fig. 5. (A) A rupture of the tibionavicular ligament (black arrow heads). (B–E) Ruptures of all ligament components. (F) A rupture of the anterior section of the deep posterior tibiotalar ligament with an intact tibiocalcaneal ligament (white arrow heads). *: ligament rupture.

In conclusion, we clarified the details of the damage pattern of the deltoid ligament in acute ankle sprains using a systematic scanning protocol. It was possible to identify the superficial and deep layers of the ligament and to observe the damage pattern of each ligament component in detail, and it appeared that ultrasonography could be used as a tool to evaluate the damage pattern of the deltoid ligament in ankle sprains. The scanning method used in this study has some issues such as its validity that need to be resolved in the future.

Study design

Retrospective case series study.

Funding

The authors received no financial support for the research, authorship, and/or publication of this article.

Declaration of competing interest

The authors declare no potential conflicts of interest with respect to the research, authorship, and/or publication of this article.

References

[1] Campbell KJ, Michalski MP, Wilson KJ, Goldsmith MT, Wijdicks CA, LaPrade RF, et al. The ligament anatomy of the deltoid complex of the ankle: a qualitative and quantitative anatomical study. J Bone Joint Surg Am 2014 Apr 16;96(8):e62.
[2] Yammine K. The morphology and prevalence of the deltoid complex ligament of the ankle. Foot Ankle Spec 2017 Feb;10(1):55–62.
[3] Barker HB, Beynnon BD, Renström PA. Ankle injury risk factors in sports. Sports Med 1997 Feb;23(2):69–74.
[4] Fong DT, Hong Y, Chan LK, Yung PS, Chan KM. A systematic review on ankle injury and ankle sprain in sports. Sports Med 2007;37(1):73–94.
[5] Hootman JM, Dick R, Agel J. Epidemiology of collegiate injuries for 15 sports: summary and recommendations for injury prevention initiatives. J Athl Train 2007 Apr-Jun;42(2):311–9.
[6] Waterman BR, Belmont Jr PJ, Cameron KL, Svoboda SJ, Alitz CJ, Owens BD. Risk factors for syndesmotic and medial ankle sprain: role of sex, sport, and level of competition. Am J Sports Med 2011 May;39(5):992–8.
[7] Kofotolis ND, Kellis E, Vlachopoulos SP. Ankle sprain injuries and risk factors in amateur soccer players during a 2-year period. Am J Sports Med 2007 Mar;35(3):458–66.
[8] Alves T, Dong Q, Jacobson J, Yablon C, Gandikota G. Normal and injured ankle ligaments on ultrasonography with magnetic resonance imaging correlation. J Ultrasound Med 2019 Feb;38(2):513–28.
[9] Sconfienza LM, Orlandi D, Lacelli F, Serafini G, Silvestri E. Dynamic high-resolution US of ankle and midfoot ligaments: normal anatomic structure and imaging technique. Radiographics 2015 Jan-Feb;35(1):164–78.
[10] Martinoli C. Musculoskeletal ultrasound: technical guidelines. Insights Imaging 2010 Jul;1(3):99–141.
[11] Precerutti M, Bonardi M, Ferrozzi G, Draghi F. Sonographic anatomy of the ankle. J Ultrasound 2013 Aug 3;17(2):79–87.
[12] Chen PY, Wang TG, Wang CL. Ultrasonographic examination of the deltoid ligament in bimalleolar equivalent fractures. Foot Ankle Int 2008 Sep;29(9):883–6.
[13] Park JW, Lee SJ, Choo HJ, Kim SK, Gwak HC, Lee SM. Ultrasonography of the ankle joint. Ultrasonography 2017 Oct;36(4):321–35.
[14] Kotnis N, Harish S, Popowich T. Medial ankle and heel: ultrasound evaluation and sonographic appearances of conditions causing symptoms. Semin Ultrasound CT MR 2011 Apr;32(2):125–41.
[15] Rosa I, Rodeia J, Fernandes PX, Teixeira R, Saldanha T, Consciência JG. Ultrasonographic assessment of deltoid ligament integrity in ankle fractures. Foot Ankle Int 2020 Feb;41(2):147–53.
[16] Henari S, Banks LN, Radovanovic I, Queally J, Morris S. Ultrasonography as a diagnostic tool in assessing deltoid ligament injury in supination external rotation fractures of the ankle. Orthopedics 2011 Oct 5;34(10):e639–43.
[17] Zaottini F, Picasso R, Pistoia F, Perez MM, Möller I, Rossi F, et al. Ultrasound imaging guide for assessment of the intrinsic ligaments stabilizing the subtalar and midtarsal joints. Semin Muscoskel Radiol 2020 Apr;24(2):113–24.
[18] Savage-Elliott I, Murawski CD, Smyth NA, Golanó P, Kennedy JG. The deltoid ligament: an in-depth review of anatomy, function, and treatment strategies. Knee Surg Sports Traumatol Arthrosc 2013 Jun;21(6):1316–27.
[19] Hung CY, Chang KV, Mezian K, Nańka O, Wu WT, Hsu PC, et al. Advanced ankle and foot sonoanatomy: imaging beyond the basics. Diagnostics (Basel) 2020 Mar 14;10(3):160.
[20] Omodani T. How to scan the deltoid ligament by ultrasound and its clarity. J Jpn Soc Orthop Ultrason 2019;30(1):182–9 [in Japanese].
[21] Chamberlain CS, Crowley E, Vanderby R. The spatio-temporal dynamics of ligament healing. Wound Repair Regen 2009 Mar-Apr;17(2):206–15.
[22] Harper MC. Deltoid ligament: an anatomical evaluation of function. Foot Ankle 1987 Aug;8(1):19–22.
[23] Jeong MS, Choi YS, Kim YJ, Kim JS, Young KW, Jung YY. Deltoid ligament in acute ankle injury: MR imaging analysis. Skeletal Radiol 2014 May;43(5):655–63.
[24] Chhabra A, Subhawong TK, Carrino JA. MR imaging of deltoid ligament pathologic findings and associated impingement syndromes. Radiographics 2010 May;30(3):751–61.
[25] Nazarenko A, Beltran LS, Bencardino JT. Imaging evaluation of traumatic ligamentous injuries of the ankle and foot. Radiol Clin North Am 2013 May;51(3):455–78.